



**QUEEN'S  
UNIVERSITY  
BELFAST**

## **Mutational spectrum of the ZEB1 gene in corneal dystrophies supports a genotype-phenotype correlation**

Lechner, J., Dash, D. P., Muszynska, D., Hosseini, M., Segev, F., George, S., Frazer, D. G., Moore, J. E., Kaye, S. B., Young, T., Simpson, D. A., Churchill, A. J., Héon, E., & Willoughby, C. E. (2013). Mutational spectrum of the ZEB1 gene in corneal dystrophies supports a genotype-phenotype correlation. *Investigative Ophthalmology and Visual Science*, 54(5), 3215-3223. <https://doi.org/10.1167/iovs.13-11781>

### **Published in:**

Investigative Ophthalmology and Visual Science

### **Document Version:**

Publisher's PDF, also known as Version of record

### **Queen's University Belfast - Research Portal:**

[Link to publication record in Queen's University Belfast Research Portal](#)

### **Publisher rights**

Copyright 2013 The Association for Research in Vision and Ophthalmology, Inc.

This work is made available online in accordance with the publisher's policies. Please refer to any applicable terms of use of the publisher.

### **General rights**

Copyright for the publications made accessible via the Queen's University Belfast Research Portal is retained by the author(s) and / or other copyright owners and it is a condition of accessing these publications that users recognise and abide by the legal requirements associated with these rights.

### **Take down policy**

The Research Portal is Queen's institutional repository that provides access to Queen's research output. Every effort has been made to ensure that content in the Research Portal does not infringe any person's rights, or applicable UK laws. If you discover content in the Research Portal that you believe breaches copyright or violates any law, please contact [openaccess@qub.ac.uk](mailto:openaccess@qub.ac.uk).

### **Open Access**

This research has been made openly available by Queen's academics and its Open Research team. We would love to hear how access to this research benefits you. – Share your feedback with us: <http://go.qub.ac.uk/oa-feedback>

# Mutational Spectrum of the *ZEB1* Gene in Corneal Dystrophies Supports a Genotype–Phenotype Correlation

Judith Lechner,<sup>1</sup> Durga P. Dash,<sup>1</sup> Dorota Muszynska,<sup>1</sup> Mohsen Hosseini,<sup>2</sup> Fani Segev,<sup>3</sup> Sonia George,<sup>4</sup> David G. Frazer,<sup>4</sup> Jonathan E. Moore,<sup>4</sup> Stephen B. Kaye,<sup>5</sup> Terri Young,<sup>6</sup> David A. Simpson,<sup>1</sup> Amanda J. Churchill,<sup>7</sup> Elise Héon,<sup>2</sup> and Colin E. Willoughby<sup>1,4,8</sup>

<sup>1</sup>Centre for Vision and Vascular Science, Queen's University Belfast, Belfast, Northern Ireland, United Kingdom

<sup>2</sup>Department of Ophthalmology and Vision Sciences, The Hospital for Sick Children, Toronto, Ontario, Canada

<sup>3</sup>Meir Medical Center, Kfar Saba, Israel

<sup>4</sup>Department of Ophthalmology, Belfast Health and Social Care Trust, Belfast, Northern Ireland, United Kingdom

<sup>5</sup>St. Paul's Eye Unit, Royal Liverpool University Hospital, Liverpool, United Kingdom

<sup>6</sup>Center for Human Genetics, Duke University Medical Center, Durham, North Carolina

<sup>7</sup>School of Clinical Sciences, University of Bristol and Bristol Eye Hospital, Bristol, United Kingdom

<sup>8</sup>Department of Eye and Vision Science, Institute of Ageing and Chronic Disease, University of Liverpool, Liverpool, United Kingdom

Correspondence: Colin E. Willoughby, Department of Eye and Vision Science, Institute of Ageing and Chronic Disease, Faculty of Health and Life Sciences, University of Liverpool, 3rd Floor, UCD Building, Daulby Street, Liverpool, L69 3GA, UK; drcolinwilloughby@googlemail.com.

JL, DPD, and DM contributed equally to the work presented here and therefore should be regarded as equivalent authors.

Submitted: January 30, 2013

Accepted: April 4, 2013

Citation: Lechner J, Dash DP, Muszynska D, et al. Mutational spectrum of the *ZEB1* gene in corneal dystrophies supports a genotype–phenotype correlation. *Invest Ophthalmol Vis Sci.* 2013;54:3215–3223. DOI:10.1167/iovs.13-11781

**PURPOSE.** Mutations in *ZEB1* have been reported in posterior polymorphous corneal dystrophy (PPCD3; MIM #609141) and Fuchs' endothelial corneal dystrophy (FECD6; MIM #613270). Although PPCD and keratoconus are clinically and pathologically distinct, PPCD has been associated with keratoconus, suggesting a common genetic basis. The purpose of our study was to perform mutational screening of the *ZEB1* gene in patients affected with keratoconus or PPCD.

**METHODS.** Sanger sequencing of *ZEB1* was performed in 70 unrelated patients with keratoconus and 18 unrelated patients with PPCD. Real-time quantitative PCR (RT-qPCR) was performed on RNA from cultured corneal keratocytes obtained from a keratoconic patient harboring a missense *ZEB1* mutation (p.Gln640His) undergoing corneal transplantation.

**RESULTS.** Mutational analysis of *ZEB1* in PPCD identified a previously reported frameshift mutation (c.1578\_1579insG) and a novel nonsense mutation (c.2249C > A) in exon 7 of *ZEB1* causing the insertion of a stop codon: p.Ser750X. In the keratoconus cohort, a novel heterozygous pathogenic mutation in exon 7 (c.1920G > T; p.Gln640His) of *ZEB1* was identified in a family affected with keratoconus and Fuchs' endothelial corneal dystrophy. RT-qPCR performed on cultured corneal keratocytes harboring the missense *ZEB1* mutation (p.Gln640His) demonstrated that *COL4A1* and *COL4A2* were markedly downregulated, and *COL4A3*, *COL4A4*, and *COL8A2* were moderately downregulated.

**CONCLUSIONS.** Our data combined with the previously reported mutational spectrum of *ZEB1* support a genotype–phenotype correlation: missense substitutions in the *ZEB1* protein are associated with FECD6 and keratoconus, whereas protein truncating *ZEB1* mutations result in PPCD3. The dysregulation of  $\alpha$ -type IV collagens represents a common link between *ZEB1* mutation and the clinical phenotypes (PPCD3, FECD, and keratoconus).

**Keywords:** keratoconus, posterior polymorphous corneal dystrophy, Fuchs' endothelial dystrophy, *ZEB1*, corneal dystrophies, hereditary

The corneal dystrophies represent a group of inherited corneal disorders that are genetically and phenotypically heterogeneous, and have been classified by phenotypic description, pathologic examination, and genetic analysis.<sup>1</sup> Posterior polymorphous corneal dystrophy (PPCD) is a rare autosomal dominant disorder of the corneal endothelium<sup>1</sup> that shows highly variable expressivity in age of presentation and clinical severity.<sup>2–4</sup> Clinically, PPCD is characterized by the presence of vesicles, bands, and geographic opacities involving the endothelium and Descemet's membrane.<sup>2,3</sup> The inter- and intrafamilial phenotypic spectrum of PPCD is wide, with some patients remaining asymptomatic with a nonprogressive

course, while others show severe progressive disease developing visual impairment due to corneal edema and requiring corneal transplantation.<sup>2,4–6</sup>

PPCD has been mapped to three different genetic loci,<sup>5,7,8</sup> and there is evidence of further genetic heterogeneity.<sup>9–11</sup> PPCD1 (MIM 605020) was mapped to chromosome 20p11.2-q11.2, and mutations were reported in visual system homeobox gene 1 (*VSX1*; MIM 605020) in PPCD and keratoconus (*KTCN1*; MIM 148300).<sup>12</sup> PPCD2 (MIM 609140) results from mutations in *COL8A2* encoding the alpha 2 chain of type VIII collagen (MIM 120252), located on chromosome 1p34.3-p32.38. Mutations in *COL8A2* also have been reported in Fuchs' endothelial

corneal dystrophy (FECD1; MIM 136800).<sup>13</sup> PPCD3 (MIM 609141) was mapped to chromosome 10p11.2 and mutations were detected in zinc finger E box-binding homeobox 1 (*ZEB1*; MIM 189909) which also is known as transcription factor 8 (*TCF8*) by some investigators.<sup>5,11</sup> Mutations in *ZEB1* account for PPCD3 in approximately 30% of PPCD patients,<sup>5,9-11</sup> and all the reported *ZEB1* mutations responsible for PPCD3 are truncating.<sup>5,9-11</sup> Missense mutations in *ZEB1* have also been reported in Fuchs' endothelial corneal dystrophy (FECD6, MIM 613270).<sup>14,15</sup>

Although PPCD, Fuchs' endothelial dystrophy, and keratoconus are clinically and pathologically distinct, keratoconus has been associated with PPCD<sup>12,16-20</sup> and Fuchs' endothelial dystrophy,<sup>16</sup> suggesting a common link.<sup>12,17-21</sup> Here, we report the results of *ZEB1* sequencing in a cohort of patients with keratoconus and PPCD. Our data combined with the previously reported mutational spectrum of *ZEB1* supports a genotype-phenotype correlation, in which protein truncating *ZEB1* mutations result in PPCD, and missense substitutions in the *ZEB1* protein are associated with keratoconus and Fuchs' endothelial dystrophy.

## METHODS

### Clinical Assessment

Patients affected with either keratoconus or posterior polymorphous corneal dystrophy were recruited as part of ongoing studies from Belfast (Belfast Health and Social Care Trust, Belfast, UK), Bristol (Bristol Eye Hospital, Bristol, UK), and Toronto (Department of Ophthalmology and Vision Sciences, The Hospital for Sick Children, University of Toronto, Toronto, Ontario, Canada). A total of 96 unrelated individuals (192 chromosomes) without ocular disease (aged 60 and over) was used as normal controls. All studies adhered to the tenets of the Declaration of Helsinki, and were approved by the relevant institutions with all participants giving written informed consent. In subjects with pathogenic sequence variants a medical history was taken to identify nonocular features previously associated with *ZEB1*: inguinal hernias, hydroceles, Dupuytren's contractures, bony lumps, spinal disease, otosclerosis, and Osgood-Schlatter disease.<sup>5,11</sup>

Patients were diagnosed with PPCD if they exhibited the characteristic endothelial changes in both eyes (vesicles, bands, or geographic opacities in the endothelium) on slit-lamp biomicroscopy. The diagnosis of keratoconus was based on well-established clinical signs on slit-lamp biomicroscopy and cycloplegic retinoscopy, and a confirmatory videokeratographic map.<sup>22,23</sup> Videokeratographic evaluation was performed on each eye using the Topographic Modelling System-1 (Computed Anatomy, Inc., New York, NY), Orbscan II (Bausch & Lomb, Salt Lake City, UT), or the Pentacam (Oculus, Wetzlar, Germany). When determining the familial segregation of *ZEB1* sequence variants, all available family members underwent clinical and topographic examination to determine their clinical status and were screened molecularly.

### DNA Extraction and Sequencing

Genomic DNA was extracted from peripheral blood leukocytes using a Wizard Genomic DNA Purification Kit (Promega, Southampton, UK) according to the manufacturer's instructions. PCR primers for amplification and sequencing of the exons, flanking intron sequences, and 5' and 3' untranslated regions (UTR) of *ZEB1* were identical to those described by Krafchak et al.<sup>5</sup> with adapted conditions, except for two additional primers for sequencing that were designed using Primer3 (v. 0.4.0) software (available in the public domain at

<http://frodo.wi.mit.edu/primer3/>)<sup>24</sup> and are listed in Supplementary Table S1. Bidirectional cycle sequencing was performed using BigDye Terminator v3.1 cycle sequencing kit (Applied Biosystems, Warrington, UK) and electrophoresed on an ABI PRISM 3730 DNA sequencer (Applied Biosystems, Warrington, UK). Sequencing results were analyzed manually using the sequence analysis software SeqScape 2.1.1 (Applied Biosystems). Identified sequence variants were described according to the guidelines published by the Human Genome Variation Society. Variants were annotated in accordance with NCBI NM\_030751.5. (Build GRCh37/hg19).

Deleterious structural effects of amino acid substitutions on protein function were assessed using the PolyPhen-2 (Polymorphism Phenotyping v2; available in the public domain at <http://genetics.bwh.harvard.edu/pph2/>),<sup>25</sup> Sorting Intolerant from Tolerant (SIFT; available in the public domain at <http://sift.jcvi.org/>),<sup>26</sup> and Pathological Mutations (PMut; available in the public domain at <http://mmb2.pcb.ub.es:8080/PMut/>)<sup>27</sup> algorithms. The conservation of the affected amino acid across species was analyzed using Homologene (available in the public domain at <http://www.ncbi.nlm.nih.gov/homologene/>) and multiple sequence alignment using the UCSC Genome Browser (available in the public domain at <http://genome.ucsc.edu/>). *ZEB1* sequence variants that were absent from controls were assessed to determine potential effects on splicing using Human Splicing Finder Version 2.4.1 (available in the public domain at <http://www.umd.be/HSF/>).<sup>28</sup>

### Human Corneal Keratocyte Cell Culture

Human corneal keratocytes were cultured directly from residual normal donor corneoscleral rims ( $n = 4$ ) and from corneal tissue obtained from a patient harboring a missense mutation in *ZEB1* (c.1920G > T; p.Gln640His) undergoing corneal transplantation. Corneal stromal tissue was dissected, fragmented, and plated on 60 mm Petri dishes. The cells were maintained separately in Dulbecco's modified Eagle's medium/nutrient Ham's F-12 (1:1) medium (Gibco; Invitrogen Ltd., Paisley, UK) supplemented with 10% fetal calf serum (FCS) and penicillin/streptomycin mix (1:1) (Sigma-Aldrich Company Ltd., Dorset, UK), at 37°C in a 5% CO<sub>2</sub> incubator (MiniGalaxy A C&M Scientific; Scientific Laboratory Supplies Ltd., Nottingham, UK). The phenotype of the cells was assessed on the basis of the distinctive morphology of human corneal keratocytes and positive vimentin (DAKO; DAKO Denmark A/S, Glostrup, Denmark), and CD34 (Santa Cruz Biotechnology, Inc., Santa Cruz, CA) immunofluorescence staining. The cultured cells also were negative for cytokeratin 3 (Millipore, Billerica, MA) immunofluorescence indicating an absence of corneal epithelial cell contamination. Cells were cultured until 90% confluence (10-14 days) and total RNA was extracted using the TRI Reagent (Sigma-Aldrich Company, Ltd.) and quantified on the Nanodrop-1000 (Nanodrop Technologies, Wilmington, DE). RNA quality was determined with the Bioanalyzer (Agilent Technologies UK Limited, Cheshire, UK).

### Real-Time Quantitative PCR (RT-qPCR)

Total RNA (1 µg) isolated from human corneal keratocytes was reverse transcribed into cDNA using the QuantiTect Reverse Transcription Kit (Qiagen, West Sussex, UK) according to manufacturer's protocol. RT-qPCR was performed by using a real-time PCR system (LightCycler 480; Roche Diagnostics, Basel, Switzerland). Primer sequences were obtained from PrimerBank (available in the public domain at <http://pga.mgh.harvard.edu/primerbank/>)<sup>29</sup> for *COL4A1*, *COL4A2*, *COL4A3*, *COL4A4*, *COL4A5*, *COL4A6*, *COL8A2*, and *ZEB1*. Real-time PCR reactions were performed in 10 µL final volume

TABLE 1. ZEB1 Sequence Variants Identified in the Posterior Polymorphous Corneal Dystrophy Patient Cohort

Nucleotide Position	Amino Acid Change	Exon/Intron	Cases	Controls	dbSNP rs #	1KG (MAF %)	ESP (MAF %)	Classification
c.192C > T	p.Asp64Asp	Exon 2	2/18	0/96	rs7918614	Yes (6.7)	Yes (6.4)	Polymorphism
c.260-136T > C	NA	Intron 2	1/18	1/96	rs2839663	Yes (1.0)	No	Polymorphism
c.1578_1579insG	p.Val526fsX2	Exon 7	Familial PPCD	0/96	NA	No	No	Pathogenic mutation
c.2061A > C	p.Pro687Pro	Exon 7	2/18	0/96	rs34846414	Yes (1.9)	Yes (1.94)	Polymorphism
c.2249C > A	p.Ser750X	Exon 7	Familial PPCD	0/96	NA	No	No	Pathogenic mutation

containing 10 ng of cDNA, gene-specific primers, and fluorescent dye SYBR green I (Fermentas UK Ltd., Cambridge, UK; conditions available on request). All PCR reactions were performed in technical triplicates. All mRNA levels were measured as CT threshold levels and were normalized with five reference genes<sup>30</sup>; glyceraldehyde-3-phosphate dehydrogenase (*GAPDH*), peptidylprolyl isomerase A (*PPIA*), ubiquitin C (*UBC*), hypoxanthine quinine phosphoribosyl transferase 1 (*HPRT1*), and ribosomal protein L5 (*RPL5*) CT values. Values were expressed as fold increase over the corresponding values for control by the  $2^{-\Delta\Delta CT}$  method. The  $\Delta Ct$  validation experiments showed similar amplification efficiency for all templates used (difference between linear slopes for all templates less than 0.1). Three independent experiments were performed and the average ( $\pm$  SEM) results were calculated using GraphPad software (GraphPad Software, San Diego, CA). Data were expressed as the mean values  $\pm$  SEM and analyzed using Student's *t*-test. Statistical differences in the mean were considered statistically significant at  $P < 0.05$ .

## RESULTS

Sanger sequencing of the entire coding region of *ZEB1* (exons 1–9) was performed on 70 unrelated patients with keratoconus (27 familial and 43 sporadic cases) and 18 unrelated patients with PPCD (7 familial and 11 sporadic cases). Pathogenicity of identified sequence variants was determined by filtering using the in-house sequencing data from 96 control subjects, data from dbSNP (Build 137), the May 2012 release of the 1000 Genomes (1 KG) Project (available in the public domain at <http://browser.1000genomes.org/index.html>), and the Exome Variant Server (EVS), NHLBI Exome Sequencing Project (ESP; Seattle, WA, available in the public domain at <http://evs.gs.washington.edu/EVS/>), segregation in familial cases, residue conservation, splicing analysis, and structural modeling.

### Mutational Analysis of ZEB1 in PPCD

In unrelated patients with PPCD ( $n = 18$ ), we identified a previously reported frameshift mutation c.1578\_1579insG (p.Val526fsX2)<sup>5</sup> and a novel nonsense mutation (c.2249C > A) in exon 7 of *ZEB1* causing the insertion of a stop codon (p.Ser750X) (Table 1, Fig. 1C). The sequence variant (c.2249C > A; p.Ser750X) was considered pathogenic as it was not seen in 192 control chromosomes or the 1KG and ESP data; and segregated with the disease phenotype in all available family members (6 affected and 2 unaffected individuals, Fig. 1A). The p.Ser750X mutation would result in a premature termination of *ZEB1* resulting in the loss of the repression domain, the second zinc finger cluster, and the acidic activation domain. The clinical features of the family affected with PPCD resulting from the *ZEB1* p.Ser750X mutation are described in Figure 1B and Supplementary Table S2.

The previously reported frameshift mutation c.1578\_1579insG (p.Val526fsX2)<sup>5</sup> was detected in a mother and son from North America. The mutation segregated in the

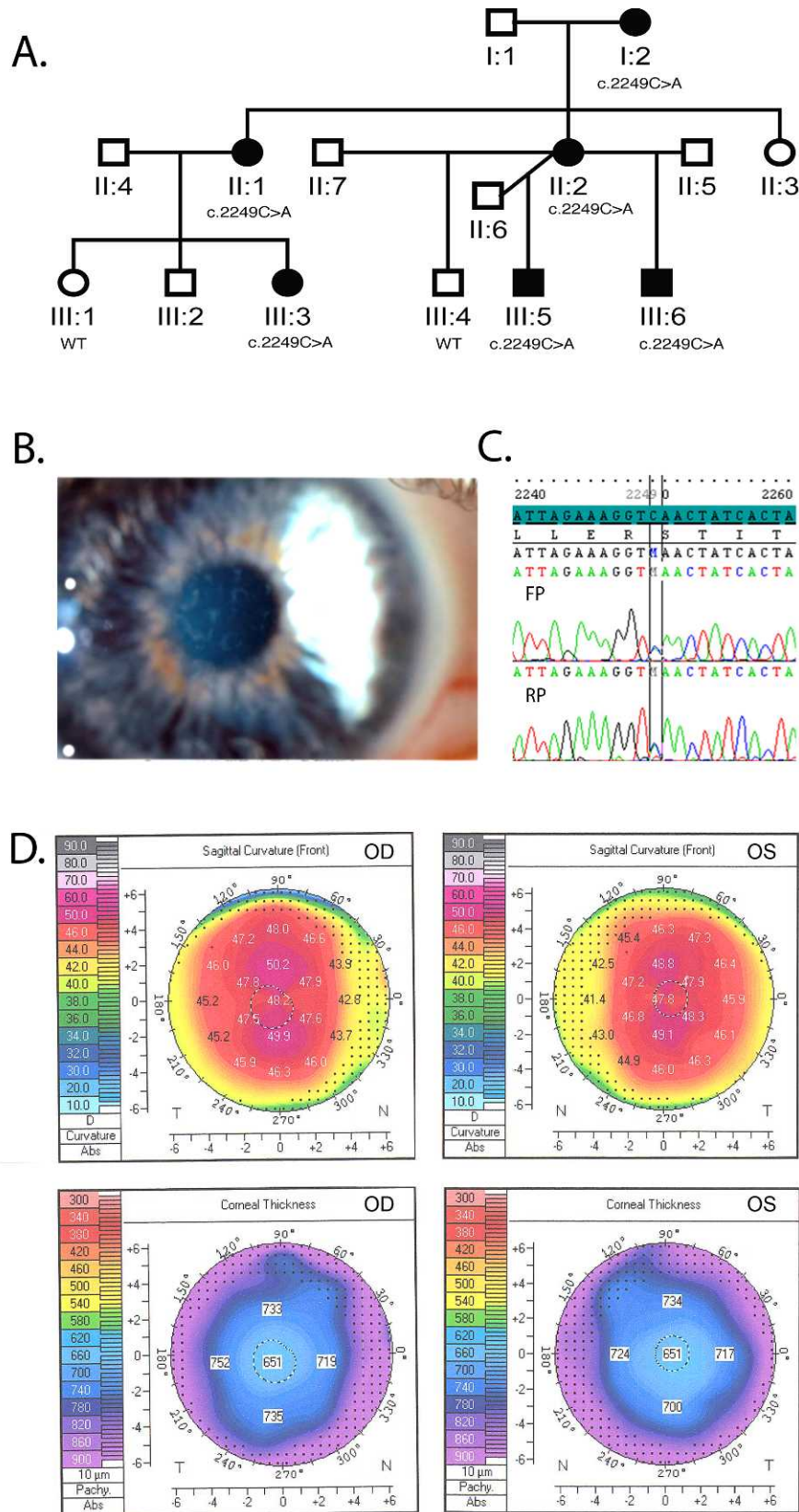
family and was not seen in the unaffected father. The proband was a 40-year-old woman with bilateral vesicles and endothelial corneal changes. Her best corrected visual acuity was of 20/25 (right eye) and 20/20 (left eye) with corrective lenses:  $-2.50$  diopters sphere (DS)/ $-0.75$  diopter cylinder (DC) at  $105^\circ$  (right eye) and  $-2.00$  DS/ $-1.25$  DC at  $76^\circ$  (left eye). Her son had normal unaided visual acuity (20/20) with a few scattered corneal endothelial vesicles. Neither patient had extraocular features reported with *ZEB1* mutation, but the proband's son had undergone Achilles tendon lengthening for his spastic diplegia resulting from cerebral palsy.

### Mutational Analysis of ZEB1 in Keratoconus

In patients with keratoconus, we identified 7 heterozygous sequence variants; 3 nonsynonymous and 4 synonymous (Table 2). Three of these were known SNPs (rs80194531, rs7918614, and rs35238902) and one was a novel SNP (c.3177A > T; p.Pro1059Pro) seen in 5% (5/96) of controls, although absent from the 1KG and EVS datasets. There were 3 novel heterozygous sequence variants (c.1574G > A: p.Gly525-Glu, c.1920G > T: p.Gln640His, and c.2673G > C: p.Pro891-Pro), which were absent from controls (192 chromosomes), and the 1KG and ESP datasets.

The novel heterozygous sequence variant exon 7, c.1574G > A (p.Gly525Glu), was identified in a patient with sporadic keratoconus. This sequence variant results in a nonconservative substitution of a nonpolar neutral amino acid (glycine) with a polar negatively charged hydrophilic residue (glutamic acid). The glycine at position 525 is well conserved in primates, although in the chicken and shrew the residue is a glutamic acid. PMut predicted that the variant was pathologic with a score of 0.8 and high reliability, whereas PolyPhen-2 and SIFT predicted this substitution was benign and tolerated, respectively. Given this evidence, we proposed that p.Gly525-Glu is classified as potentially pathogenic. As the novel synonymous change c.2673G > C (p.Pro891Pro) was absent from controls, and the 1KG and ESP datasets, we sought to determine whether there was an impact on splicing due to the impact of the nucleotide substitution on exonic splicing enhancers (ESE) and silencers (ESS).<sup>31</sup> On ESE analysis the nucleotide change c.2673G > C alters the predicted ESE binding site, but we were unable to obtain RNA from the patient to assess whether this nucleotide change results in aberrant *ZEB1* splicing.

The novel heterozygous pathogenic mutation in exon 7, c.1920G > T (p.Gln640His), was identified in two siblings with keratoconus (Fig. 2B). The nucleotide change causes the conserved polar amino acid glutamine to be substituted by the positively charged, basic amino acid histidine. The glutamine at position 640 is the last amino acid of the homeodomain, and is well conserved across primates and other vertebrates as demonstrated in Figure 2C. SIFT analysis predicted that the variant was damaging, whereas PolyPhen-2 and PMut predicted this substitution was benign and neutral, respectively.



**FIGURE 1.** (A) Segregation analysis of the c.2249C > A, p.Ser750X ZEB1 mutation in a UK family affected by PPCD. (B) Slit-lamp examination of individual II:2 showed corneal endothelial vesicles seen typically in PPCD. (C) Sequence chromatogram showing the heterozygous c.2249C > A, p.Ser750X mutation in exon 7 of ZEB1 identified in the family affected by PPCD. FP, forward primer; RP, reverse primer. (D) Pentacam corneal topography images of right (OD) and left (OS) eyes of the proband (individual II:2). The upper maps show corneal steepening with regular astigmatism, but no signs of keratoconus. The lower maps show a general increase in corneal thickness (central corneal thickness 651 μm associated with PPCD).

TABLE 2. ZEB1 Sequence Variants Identified in the Keratoconus Patient Cohort

Nucleotide Position	Amino Acid Change	Exon/Intron	Cases	Controls	dbSNP rs#	1KG (MAF %)	EVS (MAF %)	Classification
c.192C > T	p.Asp64Asp	Exon 2	1/70	0/96	rs7918614	Yes (6.7)	Yes (6.43)	Polymorphism
c.233A > C	p.Asn78Thr	Exon 2	2/70*	0/96	rs80194531	Yes (1.2)	Yes (1.68)	Polymorphism
c.1257G > A	p.Ala419Ala	Exon 7	1/70	0/96	rs35238902	Yes (1.2)	Yes (1.95)	Polymorphism
c.1574G > A	p.Gly525Glu	Exon 7	1/70	0/96	NA	No	No	Potentially pathogenic
c.1920G > T	p.Gln640His	Exon 7	Familial keratoconus and FECD	0/96	NA	No	No	Pathogenic mutation
c.2673G > C	p.Pro891Pro	Exon 8	1/70	0/96	NA	No	No	Potentially pathogenic
c.3177A > T	p.Pro1059Pro	Exon 9	3/70	5/96	NA	No	No	Polymorphism

\* Patients were African American and sequencing of ZEB1 in ethnically matched controls detected this variant in 3/23 controls.

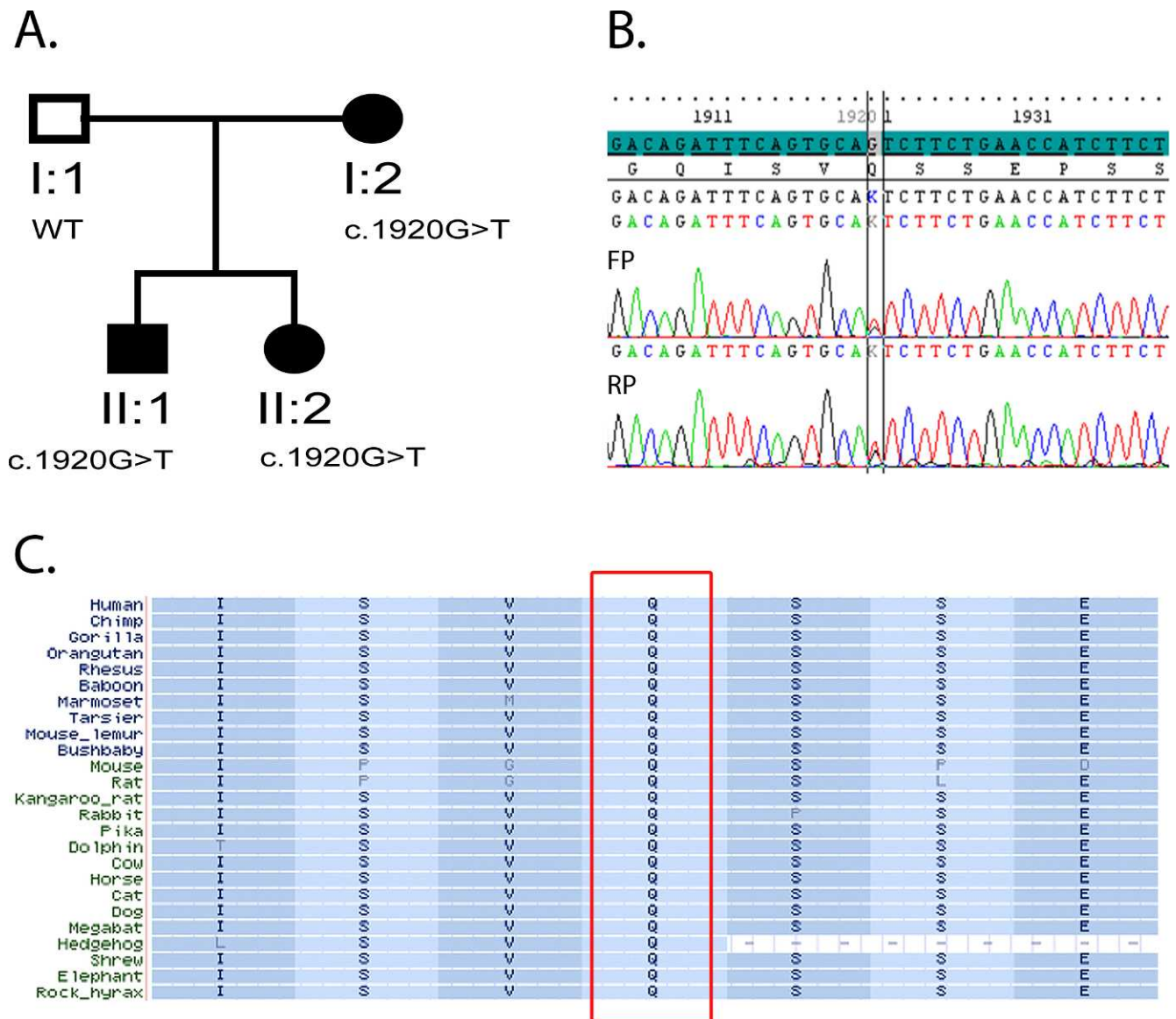
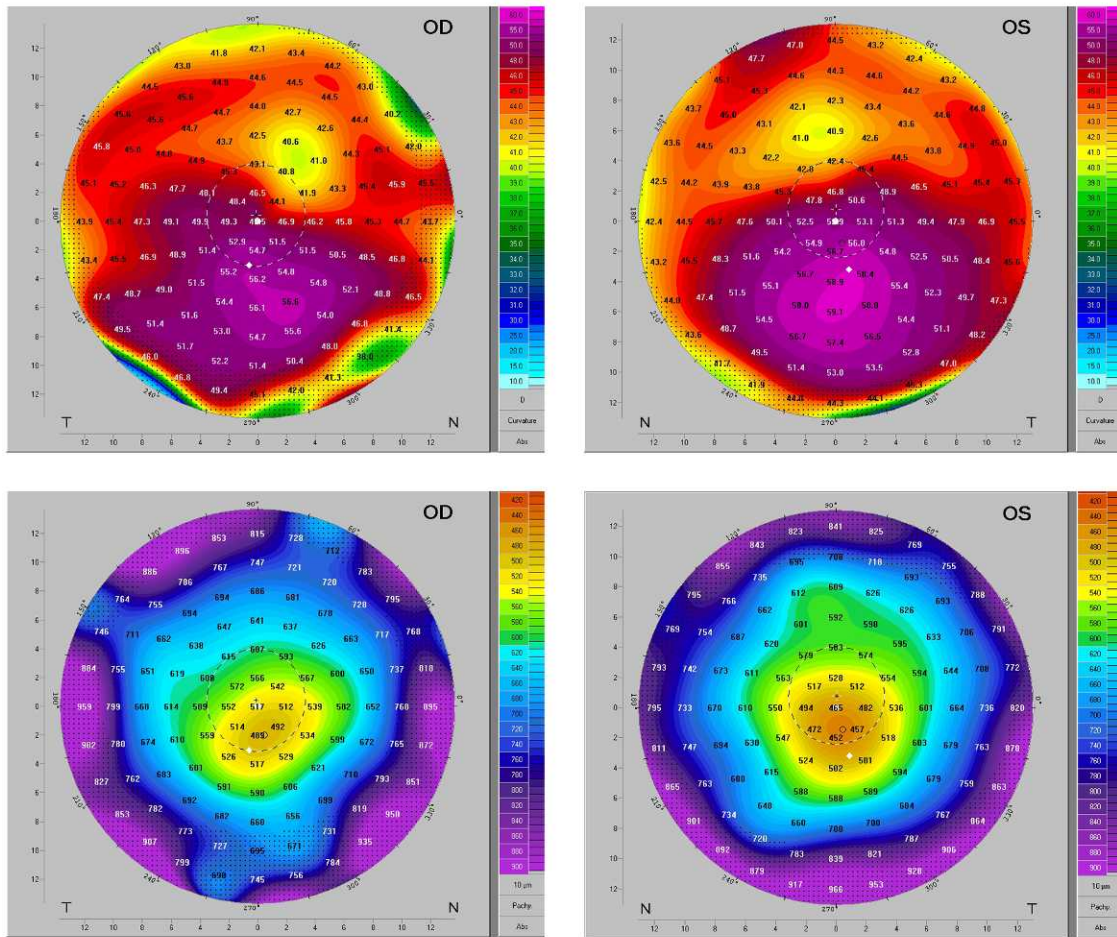
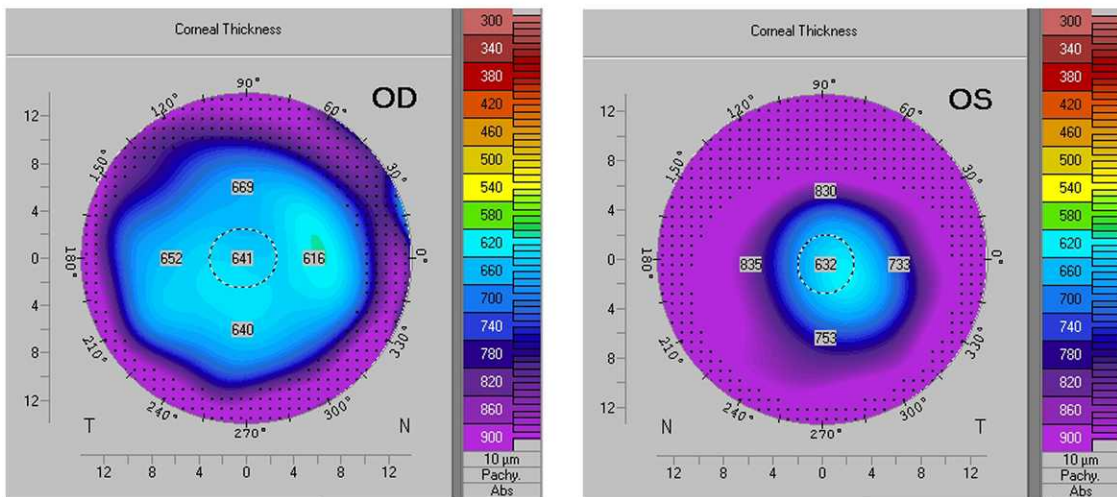


FIGURE 2. (A) Segregation analysis of the c.1920G > T, p.Gln640His ZEB1 mutation in the family affected by keratoconus (siblings) and Fuchs' endothelial corneal dystrophy (mother). (B) Sequence chromatogram showing the heterozygous c.1920G > T, p.Gln640His mutation in exon 7 of ZEB1. (C) Multiple sequence alignment showing highly conserved glutamine at position 640 in exon 7 of ZEB1.

# A. Individual II:1



# B. Individual I:2



**FIGURE 3.** (A) Pentacam corneal topography images of right (OD) and left (OS) eyes of the proband (individual II:1; Fig. 2). The *upper maps* show inferior corneal steepening with a maximal corneal power of 56.6 D (OD) and 59.1 D (OS) associated with corneal thinning (*bottom maps*) confirming keratoconus. (B) Pentacam corneal topography corneal thickness maps of the mother of the proband (individual I:2; Fig. 2). The maps show a general increase in corneal thickness especially in the right eye (OD) associated with corneal endothelial pump failure and corneal hydration associated with FECD.

**TABLE 3.** RT-qPCR of the Relative Expression Level of *ZEB1* Transcriptional Target Genes in Cultured Corneal Keratocytes Harboring the *ZEB1* Mutation p.Gln640His

Gene	<i>PPIA</i>	<i>HPRT1</i>	<i>RBL5</i>	<i>UBC</i>	<i>GAPDH</i>	Average
<i>COL4A1</i>	0.01	0.01	0.02	0.02	0.02	0.01
<i>COL4A2</i>	0.03	0.01	0.03	0.03	0.04	0.02
<i>COL4A3</i>	0.17	0.09	0.2	0.2	0.2	0.17
<i>COL4A4</i>	0.2	0.1	0.3	0.3	0.3	0.24
<i>COL4A5</i>	1	0.5	1.3	0.8	1.4	1
<i>COL4A6</i>	0.8	0.4	0.9	1.2	1	0.86
<i>COL8A2</i>	0.5	0.2	0.5	0.3	0.7	0.44
<i>ZEB1</i>	0.9	0.7	1.4	0.8	1.5	1.06

All mRNA levels were measured at CT threshold levels and were normalized with five reference genes; *PPIA*, *HPRT1*, *RPL5*, *UBC*, and *GAPDH* CT values. Values were expressed as fold increase over the corresponding values for control by the  $2^{-\Delta\Delta CT}$  method.

### Clinical Phenotype of Family With p.Gln640His *ZEB1* Mutation

The proband harboring the p.Gln640His mutation was a 39-year-old Caucasian male (individual II:1, Fig. 2A) with bilateral keratoconus. He was diagnosed at age 25 and commenced contact lens wear at age 30. His best corrected visual acuity was of 20/40 (right eye) and 20/125 (left eye) with contact lenses. On slit-lamp biomicroscopy there was definite keratoconus; there were no other anterior segment abnormalities and the endothelium was normal. The minimal corneal thickness over the apex of the cone was 488  $\mu$ m (right eye) and 448  $\mu$ m (left eye). Keratometry measurements were 49.3/46.6 D (right eye) and 51.7/49.8 D in the left eye. Corneal topography confirmed keratoconus (Fig. 3A). The patient underwent a deep anterior lamellar keratoplasty in the left eye at the age of 40 years. The patient had a 37-year-old sister affected with bilateral keratoconus (individual II:2, Fig. 2A) who carried the same mutation. She was diagnosed with keratoconus at age 19 and underwent bilateral corneal transplantation at age 28 (right eye) and 31 (left eye). Their father had normal corrected visual acuities and corneal topography. Their mother was diagnosed with Fuchs' endothelial corneal dystrophy (FECD) at age 56. FECD was diagnosed based on the presence of more than 5 mm confluent central corneal endothelial guttae in each eye (Krachmer grade 4 or higher). She underwent bilateral cataract surgery at age 58. At age 65, the patient had bilateral mild corneal epithelial and stromal edema associated with increased corneal thickness (Fig. 3B); central corneal thickness was 642  $\mu$ m (right eye) and 618  $\mu$ m (left eye). Her best corrected visual acuity was 20/40 (right eye) and 20/125 (left eye). There was no evidence of keratoconus clinically or on corneal topography. The patient underwent bilateral Descemet's stripping automated endothelial keratoplasty at age 67. Segregation

analysis identified the variant in both affected (keratoconus) siblings and the affected (FECD) mother, while it was absent in the unaffected father as shown in Figure 2A.

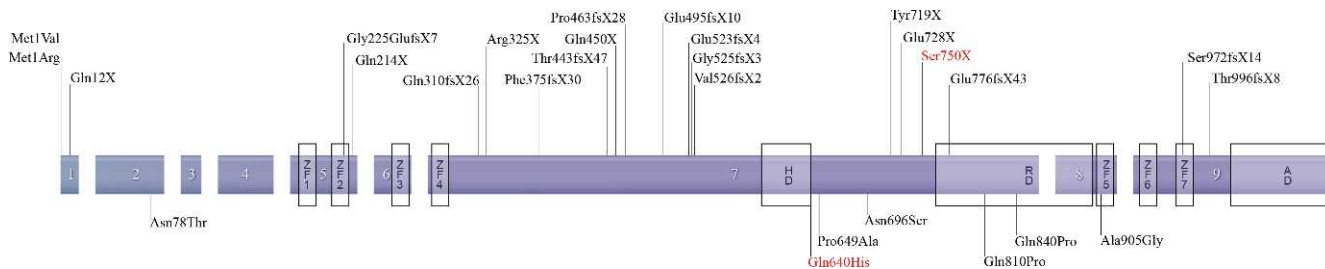
### RT-qPCR of Mutant *ZEB1* (p.Gln640His) Cultured Corneal Keratocytes

The expression of *COL8A2* and the basement collagen genes (*COL4A1*, *COL4A2*, *COL4A3*, *COL4A4*, *COL4A5*, and *COL4A6*) was evaluated by RT-qPCR in cultured corneal keratocytes obtained from a patient harboring a missense mutation in *ZEB1* (c.1920G > T, p.Gln640His, Table 3). *COL4A1* and *COL4A2* were markedly downregulated, and *COL4A3*, *COL4A4*, and *COL8A2* were moderately downregulated. The expression level of *ZEB1* was unchanged in the corneal keratocytes harboring the *ZEB1* mutation.

### DISCUSSION

*ZEB1* encodes the two-handed zinc-finger homeodomain transcription factor, which can act as either a transcriptional enhancer or repressor.<sup>32</sup> Mutations in *ZEB1* have been reported in posterior polymorphous corneal dystrophy (PPCD3; MIM #609141) and Fuchs' endothelial corneal dystrophy (FECD6; MIM #613270), and herein we report a missense mutation in *ZEB1* associated with keratoconus and highlight a genotype-phenotype correlation. Missense substitutions in the *ZEB1* protein are associated with FECD6 and keratoconus, whereas protein truncating mutations result in PPCD3 (Fig. 4, Supplementary Table S3). Genotype-phenotype correlations also exist in TGFBI (MIM #601692) associated corneal dystrophies where specific missense mutations associated with arginine at codon 124 and 555 result in different phenotypic manifestations.<sup>33,34</sup>

The largest published series reported *ZEB1* mutations in 25% of patients with PPCD (8/32 probands)<sup>11</sup> and the prevalence of mutations in *ZEB1* in PPCD has varied from 9.1% to 45.4%.<sup>5,9-11</sup> In our study *ZEB1* mutations were detected in 11.1% (2/18 probands) with PPCD. The majority of mutations were reported in exon 7, which most likely represents the relative size of this exon consisting of 1811 bps or 54% of the total *ZEB1* transcript (3375 bps). All reported *ZEB1* mutations have been unique, although the methionine at codon 1 mutation results from two different nucleotide substitutions; c.1A > G (p.Met1Val)<sup>10</sup> and c.2T > G (p.Met1Arg).<sup>11</sup> Although p.Met1Val and p.Met1Arg mutations are missense, it is predicted that they would result in a truncation of the *ZEB1* protein as the initiation of translation codon is disrupted.<sup>10</sup> All *ZEB1* mutations reported in PPCD3 are nonsense, frameshift, and missense, which result in protein truncation.<sup>5,6,9-11</sup> The proposed pathogenic mechanisms are haploinsufficiency either due to nonsense mediated decay or



**FIGURE 4.** *ZEB1* wild-type domain structure and locations of all known mutations to date. Mutations identified in PPCD patients are annotated above the gene, and mutations identified in FECD and keratoconus patients are annotated below the gene. ZF, zinc finger; HD, homeodomain; RD, repression domain; AD, activation domain.



loss of functional domains due to truncations in the ZEB1 protein, or dominant-negative effects from the truncated mutant ZEB1 protein.<sup>5</sup>

Liskova et al. failed to detect an association of keratoconus and ZEB1 mutations in their PPCD3 cohort.<sup>4</sup> Three PPCD3 patients had high keratometry readings representing corneal steepening and increased corneal refractive power (corneal power > 49 D), and no corneal thinning or other signs of keratoconus.<sup>4</sup> In our study, the keratoconus patients harboring a pathogenic missense ZEB1 mutation did not have evidence of PPCD3 and had characteristic features of keratoconus, including typical corneal topography. Missense mutations in ZEB1 have been reported in Fuchs' endothelial dystrophy (FECD6),<sup>14,15</sup> although only identified in 2% (7/384) of cases in the largest published series.<sup>14</sup> Genetic variation in the transcription factor 4 gene (TCF4; MIM602272) has been associated with the development of FECD, in a potential mechanism involving altered ZEB1 expression.<sup>35</sup>

We detected a pathogenic missense mutation in ZEB1 associated with keratoconus and FECD segregating in a family suggesting common pathophysiologic mechanisms. The dysregulation of  $\alpha$ -type IV collagens represents a common link between ZEB1 mutation and the clinical phenotypes (PPCD3, FECD, and keratoconus). Mutations in type IV collagens (COL4A3, COL4A4, and COL4A5) cause Alport syndrome, a triad of nephropathy, sensorineural deafness, and eye features that include anterior lenticonus, PPCD, and keratoconus.<sup>36</sup> Ectopic COL4A3 protein has been demonstrated in the corneal endothelium of an individual with PPCD3 resulting from a truncating mutation in ZEB1, and the expression of COL4A3 is increased in the corneal endothelium of Zeb1-null mice.<sup>37</sup> The COL4A3 promoter contains a complex promoter binding site,<sup>5</sup> and there is functional evidence that ZEB1 interacts with these proximal and distal E2-box motifs to regulate COL4A3 expression.<sup>38</sup> Altered ZEB1-mediated COL4A3 transcriptional repression resulting from truncating mutations is proposed to result in PPCD3.<sup>38</sup> In the corneal endothelium of a patient with PPCD3 resulting from a ZEB1 truncating mutation, qPCR demonstrated ZEB1 expression was reduced whereas COL4A3 expression was 4- to 5-fold higher than in the normal corneal endothelium.<sup>38</sup> However, the actual site of the truncating ZEB1 mutation and the impact on ZEB1 protein structure was not reported.<sup>38</sup> In our study, a missense mutation (p.Gln640His) in the homeodomain of ZEB1 resulted in a downregulation in  $\alpha$ -type IV collagens, whereas the expression of ZEB1 mRNA was unaltered.

ZEB1 core and secondary binding sites have been reported in the promoter sites of COL8A2 and the basement collagen genes (COL4A1, COL4A2, COL4A3, COL4A5, and COL4A6), with only the COL4A3 promoter containing a complex site consisting of the core and proximal downstream secondary sequence.<sup>5</sup> Given these findings, and that alterations in  $\alpha$ -type IV collagen have been implicated in PPCD5<sup>37,38</sup> and corneal disease,<sup>36,39,40</sup> we assessed the gene expression of COL8A2 and the basement collagen genes (COL4A1, COL4A2, COL4A3, COL4A4, COL4A5, and COL4A6) by RT-qPCR in cultured corneal keratocytes obtained from a patient harboring a missense mutation in ZEB1 (c.1920G > T; p.Gln640His). COL4A1, COL4A2, and COL4A3 expression were markedly reduced in corneal keratocytes harboring a missense ZEB1 mutation (p.Gln640His).

Reduced expression of COL4A1 and COL4A3 has been reported in keratoconus.<sup>39,40</sup> Sequencing COL4A3 and COL4A4 in 104 unrelated Slovenian patients with keratoconus did not detect mutations, although there were significant differences in the genotypes of seven previously reported polymorphisms in COL4A3 and COL4A4 between keratoconic patients and controls.<sup>41</sup> COL4A1 mutations result in a variety of ocular

defects, including abnormalities in the cornea and anterior segment.<sup>42,43</sup> Mutational screening of COL4A1 in 15 Ecuadorian keratoconus families failed to detect pathogenic variants.<sup>44</sup> Given the significant disruption in COL4A1 expression detected in our study and previously in keratoconus,<sup>39</sup> further work is required to determine the role of COL4A1 in keratoconus. We detected a reduction in COL8A2 expression in corneal keratocytes harboring a missense ZEB1 mutation (p.Gln640His). Disruption of COL8A1 and COL8A2 in a knockout mouse model resulted in corneal thinning: keratoglobus.<sup>45</sup> Missense mutations in COL8A2 result in PPCD and FECD8, although no pathologic variants have been reported in keratoconus.<sup>46</sup>

The findings reported herein and in the literature support the proposal that missense substitutions in the ZEB1 protein are associated with FECD6 and keratoconus, whereas protein truncating mutations result in PPCD3. We propose that the functional impact of the class of mutation on ZEB1 alters downstream gene expression and this forms the basis of the genotype-phenotype correlation. The identification and characterization of the molecular pathways regulated by ZEB1 in the cornea and the functional impact of mutations on these pathways is required to understand fully the observed genotype-phenotype correlations. Keratoconus and FECD result in significant ocular morbidity and are major indications for corneal transplantation.<sup>47</sup> Dissecting the role of ZEB1 in the pathogenesis of inherited corneal dystrophies will provide important insights into maintenance of corneal shape and clarity.

### Acknowledgments

The authors thank the patients who participated in our study, as well as Jude Lynch, who provided technical assistance with the construction of illustrations; Khanh-Nhat Tran-Viet (Duke University Medical Center) for assistance with DNA shipping; and Gail Billingsley and Ajoy Vincent (The Hospital for Sick Children, Toronto) for collating clinical information.

Supported by the Research and Development Office (Grant RRG Grant 4.46), Northern Ireland, Department of Education and Learning (DEL), Northern Ireland, and Fight for Sight (UK). JL is a Fight for Sight PhD student.

Disclosure: **J. Lechner**, None; **D.P. Dash**, None; **D. Muszynska**, None; **M. Hosseini**, None; **F. Segev**, None; **S. George**, None; **D.G. Frazer**, None; **J.E. Moore**, None; **S.B. Kaye**, None; **T. Young**, None; **D.A. Simpson**, None; **A.J. Churchill**, None; **E. Héon**, None; **C.E. Willoughby**, None

### References

1. Weiss JS, Moller HU, Lisch W, et al. The IC3D classification of the corneal dystrophies. *Cornea*. 2008;27(suppl 2):S1-S83.
2. Cibis GW, Krachmer JA, Phelps CD, Weingeist TA. The clinical spectrum of posterior polymorphous dystrophy. *Arch Ophthalmol*. 1977;95:1529-1537.
3. Krachmer JH. Posterior polymorphous corneal dystrophy: a disease characterized by epithelial-like endothelial cells which influence management and prognosis. *Trans Am Ophthalmol Soc*. 1985;83:413-475.
4. Liskova P, Filipic M, Merjava S, Jirsova K, Tuft SJ. Variable ocular phenotypes of posterior polymorphous corneal dystrophy caused by mutations in the ZEB1 gene. *Ophthalmic Genet*. 2010;31:230-234.
5. Krafchak CM, Pawar H, Moroi SE, et al. Mutations in TCF8 cause posterior polymorphous corneal dystrophy and ectopic expression of COL4A3 by corneal endothelial cells. *Am J Hum Genet*. 2005;77:694-708.
6. Nguyen DQ, Hosseini M, Billingsley G, Heon E, Churchill AJ. Clinical phenotype of posterior polymorphous corneal dys-

- trophy in a family with a novel *ZEB1* mutation. *Acta Ophthalmol.* 2010;88:695–699.
7. Heon E, Mathers WD, Alward WL, et al. Linkage of posterior polymorphous corneal dystrophy to 20q11. *Hum Mol Genet.* 1995;4:485–488.
  8. Biswas S, Munier FL, Yardley J, et al. Missense mutations in COL8A2, the gene encoding the alpha2 chain of type VIII collagen, cause two forms of corneal endothelial dystrophy. *Hum Mol Genet.* 2001;10:2415–2423.
  9. Liskova P, Tuft SJ, Gwilliam R, et al. Novel mutations in the *ZEB1* gene identified in Czech and British patients with posterior polymorphous corneal dystrophy. *Hum Mutat.* 2007;28:638.
  10. Vincent AL, Niederer RL, Richards A, Karolyi B, Patel DV, McGhee CN. Phenotypic characterisation and *ZEB1* mutational analysis in posterior polymorphous corneal dystrophy in a New Zealand population. *Mol Vis.* 2009;15:2544–2553.
  11. Aldave AJ, Yellore VS, Yu F, et al. Posterior polymorphous corneal dystrophy is associated with TCF8 gene mutations and abdominal hernia. *Am J Med Genet A.* 2007;143A:2549–2556.
  12. Heon E, Greenberg A, Kopp KK, et al. VSX1: a gene for posterior polymorphous dystrophy and keratoconus. *Hum Mol Genet.* 2002;11:1029–1036.
  13. Gottsch JD, Sundin OH, Liu SH, et al. Inheritance of a novel COL8A2 mutation defines a distinct early-onset subtype of fuchs corneal dystrophy. *Invest Ophthalmol Vis Sci.* 2005;46:1934–1939.
  14. Riazuddin SA, Zaghoul NA, Al-Saif A, et al. Missense mutations in TCF8 cause late-onset Fuchs corneal dystrophy and interact with FCD4 on chromosome 9p. *Am J Hum Genet.* 2010;86:45–53.
  15. Mehta JS, Vithana EN, Tan DT, et al. Analysis of the posterior polymorphous corneal dystrophy 3 gene, TCF8, in late-onset Fuchs endothelial corneal dystrophy. *Invest Ophthalmol Vis Sci.* 2008;49:184–188.
  16. Salouti R, Nowroozadeh MH, Zamani M, Ghoreyshi M. Combined anterior keratoconus and Fuchs' endothelial dystrophy: a report of two cases. *Clin Exp Optom.* 2010;93:268–270.
  17. Gasset AR, Zimmerman TJ. Posterior polymorphous dystrophy associated with keratoconus. *Am J Ophthalmol.* 1974;78:535–537.
  18. Driver PJ, Reed JW, Davis RM. Familial cases of keratoconus associated with posterior polymorphous dystrophy. *Am J Ophthalmol.* 1994;118:256–257.
  19. Weissman BA, Ehrlich M, Levenson JE, Pettit TH. Four cases of keratoconus and posterior polymorphous corneal dystrophy. *Optom Vis Sci.* 1989;66:243–246.
  20. Mazzotta C, Baiocchi S, Caporossi O, et al. Confocal microscopy identification of keratoconus associated with posterior polymorphous corneal dystrophy. *J Cataract Refract Surg.* 2008;34:318–321.
  21. Bechara SJ, Grossniklaus HE, Waring GO III, Wells JA III. Keratoconus associated with posterior polymorphous dystrophy. *Am J Ophthalmol.* 1991;112:729–731.
  22. Dash DP, George S, O'Prey D, et al. Mutational screening of VSX1 in keratoconus patients from the European population. *Eye (Lond).* 2010;24:1085–1092.
  23. Burdon KP, Macgregor S, Bykhovskaya Y, et al. Association of polymorphisms in the hepatocyte growth factor gene promoter with keratoconus. *Invest Ophthalmol Vis Sci.* 2011;52:8514–8519.
  24. Rozen S, Skaletsky H. Primer3 on the WWW for general users and for biologist programmers. *Methods Mol Biol.* 2000;132:365–386.
  25. Adzhubei IA, Schmidt S, Peshkin L, et al. A method and server for predicting damaging missense mutations. *Nat Methods.* 2010;7:248–249.
  26. Kumar P, Henikoff S, Ng PC. Predicting the effects of coding non-synonymous variants on protein function using the SIFT algorithm. *Nat Protoc.* 2009;4:1073–1081.
  27. Ferrer-Costa C, Gelpi JL, Zamakola L, Parraga I, de la Cruz X, Orozco M. PMUT: a web-based tool for the annotation of pathological mutations on proteins. *Bioinformatics.* 2005;21:3176–3178.
  28. Desmet FO, Hamroun D, Lalande M, Collod-Beroud G, Claustres M, Beroud C. Human Splicing Finder: an online bioinformatics tool to predict splicing signals. *Nucleic Acids Res.* 2009;37:e67.
  29. Wang X, Spandidos A, Wang H, Seed B. PrimerBank: a PCR primer database for quantitative gene expression analysis, 2012 update. *Nucleic Acids Res.* 2012;40:D1144–D1149.
  30. Ren S, Zhang F, Li C, et al. Selection of housekeeping genes for use in quantitative reverse transcription PCR assays on the murine cornea. *Mol Vis.* 2010;16:1076–1086.
  31. Cartegni L, Chew SL, Krainer AR. Listening to silence and understanding nonsense: exonic mutations that affect splicing. *Nat Rev Genet.* 2002;3:285–298.
  32. Vandewalle C, Van Roy F, Bex G. The role of the ZEB family of transcription factors in development and disease. *Cell Mol Life Sci.* 2009;66:773–787.
  33. Korvatska E, Munier FL, Djemai A, et al. Mutation hot spots in 5q31-linked corneal dystrophies. *Am J Hum Genet.* 1998;62:320–324.
  34. Munier FL, Frueh BE, Othenin-Girard P, et al. BIGH3 mutation spectrum in corneal dystrophies. *Invest Ophthalmol Vis Sci.* 2002;43:949–954.
  35. Baratz KH, Tosakulwong N, Ryu E, et al. E2-2 protein and Fuchs's corneal dystrophy. *N Engl J Med.* 2010;363:1016–1024.
  36. Colville DJ, Savage J. Alport syndrome. A review of the ocular manifestations. *Ophthalmic Genet.* 1997;18:161–173.
  37. Liu Y, Peng X, Tan J, Darling DS, Kaplan HJ, Dean DC. *Zeb1* mutant mice as a model of posterior corneal dystrophy. *Invest Ophthalmol Vis Sci.* 2008;49:1843–1849.
  38. Yellore VS, Rayner SA, Nguyen CK, et al. Analysis of the role of ZEB1 in the pathogenesis of posterior polymorphous corneal dystrophy. *Invest Ophthalmol Vis Sci.* 2012;53:273–278.
  39. Stachs O, Bochert A, Gerber T, Koczan D, Thiessen HJ, Guthoff RF. The extracellular matrix structure in keratoconus [in German]. *Ophthalmologe.* 2004;101:384–389.
  40. Kenney MC, Nesburn AB, Burgeson RE, Butkowsky RJ, Ljubimov AV. Abnormalities of the extracellular matrix in keratoconus corneas. *Cornea.* 1997;16:345–351.
  41. Stabuc-Silih M, Ravnik-Glavac M, Glavac D, Hawlina M, Strazisar M. Polymorphisms in COL4A3 and COL4A4 genes associated with keratoconus. *Mol Vis.* 2009;15:2848–2860.
  42. Coupry I, Sibon I, Mortemousque B, Rouanet F, Mine M, Goizet C. Ophthalmological features associated with COL4A1 mutations. *Arch Ophthalmol.* 2010;128:483–489.
  43. Gould DB, Marchant JK, Savinova OV, Smith RS, John SW. Col4a1 mutation causes endoplasmic reticulum stress and genetically modifiable ocular dysgenesis. *Hum Mol Genet.* 2007;16:798–807.
  44. Karolak JA, Kulinska K, Nowak DM, et al. Sequence variants in COL4A1 and COL4A2 genes in Ecuadorian families with keratoconus. *Mol Vis.* 2011;17:827–843.
  45. Hopfer U, Fukai N, Hopfer H, et al. Targeted disruption of Col8a1 and Col8a2 genes in mice leads to anterior segment abnormalities in the eye. *FASEB J.* 2005;19:1232–1244.
  46. Aldave AJ, Bourla N, Yellore VS, et al. Keratoconus is not associated with mutations in COL8A1 and COL8A2. *Cornea.* 2007;26:963–965.
  47. Tan DT, Dart JK, Holland EJ, Kinoshita S. Corneal transplantation. *Lancet.* 2012;379:1749–1761.