



**QUEEN'S
UNIVERSITY
BELFAST**

Description and etiology of paleopathological lesions in the type specimen of *Parasaurolophus walkeri* (Dinosauria: Hadrosauridae), with proposed reconstructions of the nuchal ligament

Bertozzo, F., Manucci, F., Dempsey, M., Tanke, D. H., Evans, D. C., Ruffell, A., & Murphy, E. (2021). Description and etiology of paleopathological lesions in the type specimen of *Parasaurolophus walkeri* (Dinosauria: Hadrosauridae), with proposed reconstructions of the nuchal ligament. *Journal of Anatomy*, 238(5), 1055-1069. Article 14. <https://doi.org/10.1111/joa.13363>

Published in:
Journal of Anatomy

Document Version:
Publisher's PDF, also known as Version of record

Queen's University Belfast - Research Portal:
[Link to publication record in Queen's University Belfast Research Portal](#)

Publisher rights

© 2020 The Authors.

This is an open access Creative Commons Attribution-NonCommercial License (<https://creativecommons.org/licenses/by-nc/4.0/>), which permits use, distribution and reproduction for non-commercial purposes, provided the author and source are cited.

General rights

Copyright for the publications made accessible via the Queen's University Belfast Research Portal is retained by the author(s) and / or other copyright owners and it is a condition of accessing these publications that users recognise and abide by the legal requirements associated with these rights.

Take down policy

The Research Portal is Queen's institutional repository that provides access to Queen's research output. Every effort has been made to ensure that content in the Research Portal does not infringe any person's rights, or applicable UK laws. If you discover content in the Research Portal that you believe breaches copyright or violates any law, please contact openaccess@qub.ac.uk.

Open Access

This research has been made openly available by Queen's academics and its Open Research team. We would love to hear how access to this research benefits you. – Share your feedback with us: <http://go.qub.ac.uk/oa-feedback>

ORIGINAL PAPER

Description and etiology of paleopathological lesions in the type specimen of *Parasaurolophus walkeri* (Dinosauria: Hadrosauridae), with proposed reconstructions of the nuchal ligament

Filippo Bertozzo^{1,2}  | Fabio Manucci³ | Matthew Dempsey⁴ | Darren H. Tanke⁵ | David C. Evans^{6,7} | Alastair Ruffell¹ | Eileen Murphy¹

¹School of Natural and Built Environment, Queen's University Belfast, Belfast, UK

²CI2Paleo, Sociedade de Historia Natural, Torres Vedras, Portugal

³Associazione Paleontologica Paleoaestiva Italiana, Parma, Italy

⁴Department of Musculoskeletal & Ageing Science, University of Liverpool, Liverpool, UK

⁵Royal Tyrrell Museum of Paleontology, Drumheller, AB, Canada

⁶Royal Ontario Museum, Toronto, ON, Canada

⁷Ecology and Evolutionary Biology, University of Toronto, Toronto, ON, Canada

Correspondence

Filippo Bertozzo, School of Natural and Built Environment, Queen's University Belfast, Belfast, Northern Ireland, UK. Email: f.bertozzo@qub.ac.uk

Funding information

Dinosaur Research Institute Student Project, Grant/Award Number: 2018; Horizon 2020 research and innovation programme under the MSCA grant agreement, Grant/Award Number: 754507

Abstract

Paleopathology, or the study of ancient injuries and diseases, can enable the ecology and life history of extinct taxa to be deciphered. Large-bodied ornithomimids are the dinosaurs with the highest frequencies of paleopathology reported to-date. Among these, the crested hadrosaurid *Parasaurolophus walkeri* is one of the most famous, largely due to its dramatic elongated and tubular nasal crest. The holotype of *Parasaurolophus walkeri* at the Royal Ontario Museum, Canada, displays several paleopathologies that have not been discussed in detail previously: a dental lesion in the left maxilla, perhaps related to periodontal disease; callus formation associated with fractures in three dorsal ribs; a discoidal overgrowth above dorsal neural spines six and seven; a cranially oriented spine in dorsal seven, that merges distally with spine six; a V-shaped gap between dorsal spines seven and eight; and a ventral projection of the pubic process of the ilium which covers, and is fused with, the lateral side of the iliac process of the pubis. These lesions suggest that the animal suffered from one or more traumatic events, with the main one causing a suite of injuries to the anterior aspect of the thorax. The presence of several lesions in a single individual is a rare observation and, in comparison with a substantial database of hadrosaur paleopathological lesions, has the potential to reveal new information about the biology and behavior of these ornithomimids. The precise etiology of the iliac abnormality is still unclear, although it is thought to have been an indirect consequence of the anterior trauma. The discoidal overgrowth above the two neural spines also seems to be secondary to the severe trauma inflicted on the ribs and dorsal spines, and probably represents post-traumatic ossification of the base of the nuchal ligament. The existence of this structure has previously been considered in hadrosaurs and dinosaurs more generally through comparison of origin and insertion sites in modern diapsids (*Rhea americana*, *Alligator mississippiensis*, *Iguana iguana*), but its presence, structure, and origin-attachment sites are still debated. The V-shaped gap is hypothesized as

This is an open access article under the terms of the Creative Commons Attribution-NonCommercial License, which permits use, distribution and reproduction in any medium, provided the original work is properly cited and is not used for commercial purposes.

© 2020 The Authors. *Journal of Anatomy* published by John Wiley & Sons Ltd on behalf of Anatomical Society

representing the point between the stresses of the nuchal ligament, pulling the anterior neural spines forward, and the ossified tendons pulling the posterior neural spines backward. Different reconstructions of the morphology of the structure based on the pathological conditions affecting the neural spines of ROM 768 are proposed. Finally, we review the history of reconstructions for *Parasaurolophus walkeri* showing how erroneous misconceptions have been perpetuated over time or have led to the development of new hypotheses, including the wide neck model supported in the current research.

KEYWORDS

Alberta, Cretaceous, nuchal ligament, Ornithopoda, trauma

1 | INTRODUCTION

Among hadrosaurs (a.k.a. the “duck-billed” dinosaurs), *Parasaurolophus walkeri* (Parks, 1922) is one of the genera best-known among the general public iconically due to its posteriorly and downward directed, hollow, tubular crest. The genoholotypic specimen was described by Parks (1922), and comprised a nearly complete skeleton (ROM 768) discovered in the Dinosaur Park Formation in today's Dinosaur Provincial Park (DPP, Alberta, Canada) in 1920 by a team from the University of Toronto. The specimen is lacking the caudal series, hindlimbs (only the left femur is preserved), and distal ends of the ischia (Parks, 1922; Figure 1a). Unfortunately, no other complete or articulated skeletons have been confirmed in this area since, making it one of the rarest and most enigmatic hadrosaur species from the DPP (Evans et al., 2007, 2009; Ryan & Evans, 2005). Additional *Parasaurolophus* specimens have been discovered in the Fruitland Formation (*P.cyrtochristatus*; Ostrom, 1961) and the Kirtland Formation (Sullivan & Williamson, 1999; Wiman, 1931) in New Mexico, USA. Recently, several specimens have been collected from the Kaiparowits Formation of Utah (Gates et al., 2013), including an exquisite near-complete juvenile skeleton (Farke et al., 2013). Isolated skeletal material is often found scattered in these regions, but complete specimens are limited to those reported so far. The paleobiology of *Parasaurolophus* has attracted the attention of researchers, largely because of its exaggerated and unusual crest. As for other lambeosaurine dinosaurs, it has been variously proposed that, in addition to visual display, the crest facilitated underwater feeding, was involved with thermoregulation or improving olfaction, or that its internal structures functioned as resonating chambers, which is the most widely accepted hypothesis (see review by Evans, 2006, and an exhaustive list of references in Weishampel, 1981).

The holotype of *P.walkerii* reveals further information about the biology and life history of the individual itself. The specimen displays a wide number of fossilized injuries in the postcranial skeleton, as noted by Parks (1922), as well as a previously undescribed dental pathology in the upper jaw. Parks (1922) did not extensively describe the lesions and their possible causes in detail; however, doing so is one of the aims of the present paper. The lesions comprise dental disease in the left maxilla; a roughened bony plate on the distal tips

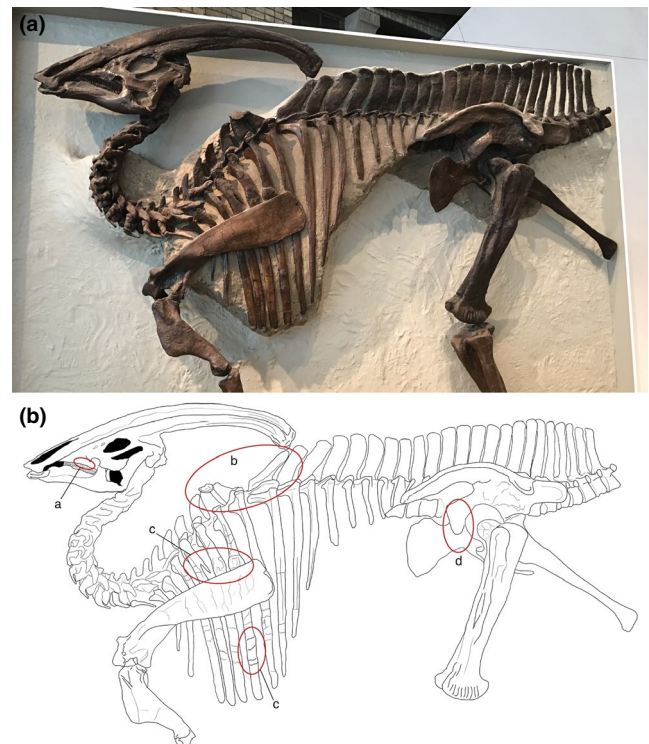


FIGURE 1 (a) The type specimen of *Parasaurolophus walkeri* (ROM 768) exhibited at the ROM in the opisthotonic “death pose” position as it was found in 1920; (b) simplified skeletal drawing of ROM 768, in which the red circles indicate the positions of the paleopathological lesions: (a) dental disease, (b) V-shaped gap of neural spines (“saddle”) and discoidal overgrowth, (c) fractures of the ribs, and (d) irregular overgrowth of the pubic peduncle of the ilium

of the neural spines of dorsal vertebrae six and seven; a V-shaped deformation of the neural spines of dorsal vertebrae seven and eight; a bony spur on the fourth dorsal rib; callus formation on the fifth and sixth dorsal ribs; and a ventral projection of the pubic peduncle of the left ilium (Figure 1b). During Parks' time, interest in dinosaur paleopathology was in its infancy (see Moodie, 1923), and no proper references or comparative material were available. Today, based on subsequent large collections of skeletons and skeletal material, we know that large ornithopod dinosaurs have the highest

frequency of fossilized injuries and diseases among the dinosaurian fossil record (Bertozzo et al. in prep; Rothschild et al., 2003; Siviero et al., 2020; Tanke & Rothschild, 2002, 2014). In addition, new research and technologies over the past 30 years have provided a larger sample of pathological specimens for comparative purposes, as well as enabling a better understanding to be gained of the external and internal structure of fossilized lesions and diseases in dinosaurs. Among the injuries recorded in ROM 768, those affecting the neural spines of the dorsal vertebrae have been the subject of much attention over the decades, especially among non-specialist publications for the general public. At first sight, this “opening” of the neural spines is located virtually below the distal end of the nasal crest, hence Andrew Milner hypothesized that this represented a “saddle”-like concavity on the anterior torso midline to receive the crest when the animal was moving its head from side-to-side (see Norman, 1985, p. 126). Initially, Parks thought that the neural spine configuration in *P.walkerii* was pathological but, in the same paper, he then revised this view to suggest that the odd discoidal overgrowth on top of the rostrally facing neural spines served as an attachment point for muscles or tendons linked directly to the distal crest (Parks, 1922, p. 18). Later, Russell (1946) suggested the fusion of the neural spines would have supported strong cervical musculature for the large head during underwater feeding. No further research focused on this feature, and the debate about its pathological nature has never been fully resolved, despite some researchers agreeing with Parks’ initial pathological hypothesis (see Lull & Wright, 1942; Naish, 2008; Ostrom, 1962). In this paper, we provide a detailed morphological description of the injuries in the *P.walkerii* holotype and compare them with examples previously identified in Ornithopoda and other dinosaurs. The possible nature of the “saddle” and bone overgrowth on the dorsal spines as a ligament attachment site for the crest are reviewed. Finally, an ecological explanation for the causes of the injuries, which we suggest may have happened in one to perhaps three event(s) during the lifetime of the individual, is provided.

2 | MATERIALS AND METHODS

Parasaurolophus walkerii (ROM 768) is panel-mounted at Royal Ontario Museum (ROM) in an articulated pose, with the left side exposed, whilst the original skull is kept in the collection and a cast completes the mount. The axial skeleton is rigidly fixed to the panel mount, and the postcranial elements could not be removed to facilitate an internal analysis via CT scanning. As reported by several authors (Anné et al., 2015, 2016; Ekhtiari et al., 2020; Hedrik et al., 2016; Jentgen-Ceschino et al., 2020; Redelstorff et al., 2015), diagnoses of fossilized injuries and diseases can be improved through the use of internal analytical techniques such as histology, (micro)CT scans, and synchrotron. Unfortunately, ROM 768 cannot be disassembled from the mount and, therefore, this study solely focuses on the external morphology while bearing in mind the difficulties of providing detailed diagnoses using such an approach. The elements were photographed with a Sony Mirrorless a5100 camera, a 10-cm scale bar was placed

next to the bones where possible, and measurements were taken with a 1-m tape. The morphological analysis of the pathologies aimed to recognize: (a) reactive bone surfaces; (b) new bone formation; (c) the presence of underlying original bone tissue; and (d) drainage sinuses for the release of infectious material. The identified lesions were compared with another specimen, referred to as cf. *Parasaurolophus* (TMP 1992.053.0021), as well as those included in the increasing database of fossilized injuries and diseases of dinosaurs and other extinct vertebrates (e.g., Bertozzo et al. in prep; Barbosa et al., 2016, 2018; Molnar, 2001; Tanke & Rothschild, 2002, 2014; Senter & Juengst, 2016; Hunt et al., 2019). To facilitate description of the presence of the nuchal ligament in *P.walkerii*, and its connection to the purported pathological neural spines, the origins, insertions, and structure of the nuchal ligament were created based on reconstructions for extant crocodiles and birds (Tsuihiji, 2004; Yasuda, 2002), sauropods (Woodruff, 2017), and mammals (Bertram & Gellman, 2002; Fielding et al., 1976; Kadri & Al-Mefty, 2007; May-Davis & Kleine, 2014).

A visual representation of the traumatic event that may have been responsible for causing some of the injuries in ROM 768 is provided later, in Figure 6. We further reviewed the history of scientific reconstructions of *Parasaurolophus* to highlight the anatomical changes and the mistakes made in depictions of the species over the years. The importance of the relationship between the reconstructions and the paleopathological lesions is emphasized (following Bertozzo et al., 2017).

2.1 | Institutional Abbreviations

AMNH, American Museum of Natural History, New York, USA; CMN, Canadian Museum of Nature, Ottawa, Canada; CUST, Museum of Natural History, Jilin University, Changchun, P.R. China; DPP, Dinosaur Provincial Park, Alberta, Canada; FMNH, Field Museum of Natural History, Chicago, Illinois, USA; GMH, Geological Museum of Heilongjiang, Heilongjiang Province, P.R. China; GPDM, Great Plains Dinosaur Museum, Malta, USA; LACM, Los Angeles County Museum, Los Angeles, California, USA; MCD, Museu de la Conca Dellà, Isona, Spain; MOR, Museum of the Rockies, Bozeman, Montana, USA; MPZ, Museo Paleontológico de la Universidad de Zaragoza, Zaragoza, Spain; ROM, Royal Ontario Museum, Toronto, Ontario, Canada; TMP, Royal Tyrrell Museum of Palaeontology, Drumheller, Alberta, Canada; ZPAL, Institute of Paleobiology, Polish Academy of Sciences, Warsaw, Poland.

3 | RESULTS AND DISCUSSION

The paleopathological lesions evident in ROM 768 are of one to three putative different etiologies: the skull suffered from periodontal disease in the alveolar bone of a group of maxillary teeth; the thorax was hit at least once by an external object, resulting in localized injuries; and the ilium displays a hypertrophic extension of the pubic peduncle that covered a small portion of the underlying pubic

blade and may have been secondary to the injuries of the thorax. Each group of lesions will be described in detail below.

3.1 | Maxilla

The margins of the teeth display a swollen area around the midpoint of the external side of the left maxilla, slightly inferior to the maxillary facet of the jugal. The affected area has rounded and smooth margins, suggestive of a healed and long-standing nature, and extend for the length of (approximately) seven teeth at their eruption point (Figure 2a). Similar conditions have been recognized in the maxillae of CMN 362 ("*Stephanosaurus*;" Tanke & Rothschild, 2014; Figure 2b) and AMNH FARB 6390 (*Bactrosaurus johnsoni*; FB, pers. obs.). Although the latter specimen shows a milder condition with just an upturn of the maxillary margins of the teeth, the lesion in CMN 362 had a more severe impact on the bone (FB, pers. obs.), although a more detailed study is needed to assess the potential impact on the lifestyle of the individual. Differential diagnosis for the lesion in ROM 768, and consequently in CMN 362 and AMNH FARB 6390, includes periodontal disease, infection (maxillary abscess), and traumatic injury. However, internal analysis through CT and microCT scans is required in the future to enable a more reliable description of the bone tissue, and possibly determine the chronicity of the condition.

3.2 | Dorsal vertebrae

The lesions in the dorsal vertebrae are the most striking pathological feature present. The neural spines of dorsal seven and eight are spread apart, facing rostrally and caudally respectively. The angle of this deformation (calculated from the central point of the distal

margin of the spines to the articulation between the rib capitulum/prezygapophysis point; Figure 3) is 110°. Dorsal spine eight bears a small knob anteriorly and, from this point up to the distal tip of the spine, the anterior margin is slightly concave, a shape not visible in any other dorsal spines. The three dorsal spines succeeding the deformed area are angled slightly caudally. In all other hadrosaurid taxa, the dorsal spines are angled caudally in cranial dorsal vertebrae and gradually become more vertical caudally along the mid-dorsal and posterior dorsal vertebrae (e.g., Campione, 2014; Godefroit et al., 2012). A marked difference in the length and width of the two spines in ROM 768 is also evident. In the hadrosaur dorsal series, the length of the spines usually increases regularly from the cervicodorsal transition to the more posterior dorsals, without marked deviations in height (at least, in the dorsal series; hadrosaurid taxa show different lengths of vertebral spines in the sacral and proximal caudal regions; Horner et al., 2004). The spines are straight, and no apparent major fracturing, truncation or deflection are visible on their bodies. However, on dorsals nine, 10 and perhaps 11, there seems to be a horizontal "fascia" of deformation, and the lower half of those spines are slightly swollen.

A small, enlarged area (callus?) is visible emerging from the right prezygapophysis of dorsal eight (Figure 3d); Lull and Wright (1942) previously reported on this modified zygapophyseal articulation. The rostral-most margin of the neural spine of dorsal seven is fused with the caudal margin of the spine of dorsal six via an abnormal overgrowth of bone (Figure 3b). This overgrowth has the shape of a flat disk of consistent thickness with a highly remodeled and porotic surface (Figure 3c). Parks (1922) described it as: "[...] a discoidal expansion or co-ossified separate bone about 100 mm in diameter and 20 mm thick." The "dorsal" surface is subcircular and more developed on the right side and covers the entire dorsal surface of the anterior neural spine.

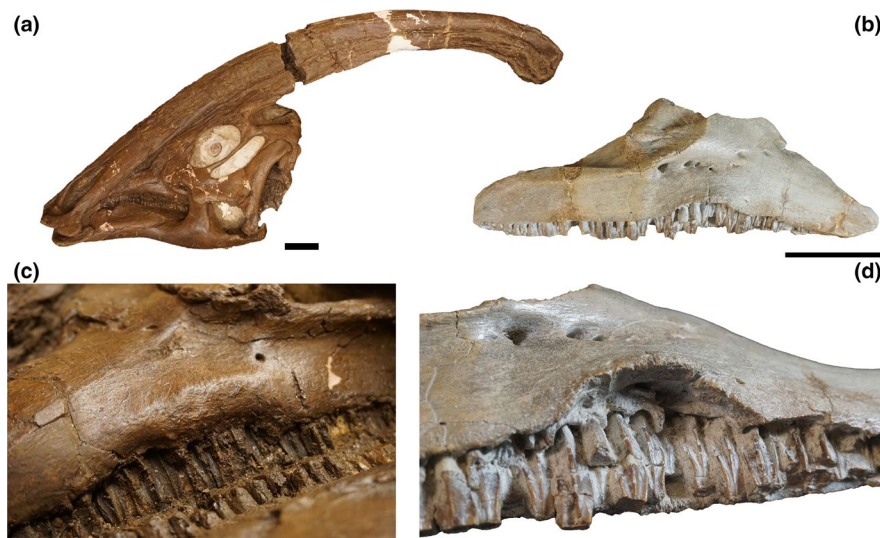

FIGURE 2 (a) skull of *Parasauroplophus walkeri* ROM 768 in left lateral view; (b), isolated right maxilla of "*Stephanosaurus*" (CMN 362) in lateral view; (c), detail of the ventral margin of the left side of the maxilla, highlighting the disease of the central portion of the alveolar margin; (d), detail of the maxilla of CMN 362, highlighting the everted ventral margin, with the exposed alveolar base of the maxillary teeth. Scale bar =10 cm

FIGURE 3 (a) anterior dorsal vertebrae of ROM 768, showing the V-like deformation between the neural spines of vertebrae seven and eight. The dotted line demarcates the “saddle” as described in the text; (b), the discoidal overgrowth on top of dorsal vertebra six, fusing at the apical portion with that of dorsal vertebra seven; (c), dorsal view of the discoidal overgrowth; (d), latero-caudal view of the articulation between dorsal vertebrae six and seven, focusing on the enlarged, callus-like appearance of the prezygapophysis. Abbreviations: **do**, discoidal overgrowth; **c.prz**, callus on prezygapophysis





FIGURE 4 (a) ROM 768 dorsal ribs connected to dorsal vertebrae five, six and seven. The first injury is associated with a bony spur, while the shaft is enlarged by callus formation on the fifth and sixth rib. (b), two small calluses at the distal region of the sixth rib, separated by a shallow surface. (c), TMP 1992.053.0021, cranial view showing callus next to the rib neck, with a detail of the medial view (d). (e) TMP 1992.053.0021, cranial view of a rib showing callus formation on the upper third of the shaft, with a detail of the medial view (f). (g), TMP 1992.053.0021, cranial view of a shorter rib showing callus at the neck, with a detail of the medial view (h). The arrows point to the pathological areas. Scale bar in a, b, c, e, and g = 10 cm; scale bar in d, f, h = 5 cm



3.3 | Ribs

The fourth, fifth, and sixth dorsal ribs in ROM 768 show signs of simple fractures on their shafts (Figure 4a). The fourth rib bears a pointed, elongated spur that diverges from the main rib shaft by

an angle of 15°. The bone surface at the base of this overgrowth is roughly remodeled, but no resorption or recesses (draining channels or small cavities) are evident. The spur has a straight outline. The fifth rib has a modest cranio-caudal enlargement, attributable to callus formation. A more expanded and developed area of

callus is evident in the sixth rib. These areas have a rougher texture than the “healthy” portions of the bone, but the appearance of the callus is an indication of the advanced state of healing of the bones. In addition, the sixth rib bears two, less distinct calluses at the distal region (Figure 4b). The scapula shows no evidence of injuries, despite scapular trauma having been previously identified in hadrosaurs (Tanke & Rothschild, 2002), and it may physically cover additional rib fractures. The morphology of the callus formation associated with the rib injuries indicates that they had all healed to a similar extent when the animal died, suggesting they were probably attained at the same time. Previous research has identified a variety of injuries in the rib cage of hadrosaurs (Tanke & Rothschild, 2014; Bertozzo et al. in prep), thereby demonstrating how the lateral sides of the trunk in these dinosaurs were susceptible to trauma. Bertozzo et al. (2017) and Tanke and Rothschild (2014) have suggested that such injuries can be a byproduct of intraspecific fighting, a behavior also witnessed in modern mammals and varanid lizards. To extend the current knowledge of pathological ribs in *Parasaurolophus*, and for comparison with ROM 768, three further pathological ribs that belong to another cf. *Parasaurolophus* sp., but in an incomplete and disarticulated condition, are reported here (Figure 4c–h). TMP 1992.053.0021 was discovered by one of the authors (DHT) in 1992 in the Dinosaur Park Formation (DPP, Alberta, Canada). The three pathological ribs are mostly complete, although one of them is missing half of the shaft (Figure 4e). Callus formation is evident on each rib, two of which are located beneath the neck of the capitulum along the curved portion of the proximal region (Figure 4c–d, g–h), while the larger rib displays callus at its midshaft (Figure 4e, f). Similar to ROM 768, the calluses all present the same state of healing with irregular and remodeled surfaces, suggesting they had all

been attained during a single traumatic event. In comparison to the fractures of ROM 768, the injuries in the ribs of TMP 1992.053.0021 are at different locations and the callus is smoother in appearance, thereby suggesting a more advanced state of healing. Another example of a healing fractured rib was found in MOR 548, a hatchling *Hypacrosaurus* from Montana, with a small callus in the shaft (FB, pers. obs.), suggesting that hadrosaurs were able to survive thoracic injuries attained at a relatively young age. The etiology of the healing rib fractures in these hadrosaurs cannot be confirmed with certainty but, given their location (most are located on the shaft rather than the head or neck areas of the ribs), it is considered feasible that they might have resulted from intraspecific fighting (Bertozzo et al., 2017); failed predation (Tanke & Rothschild, 2014); impacts from falling objects, such as trees or rocks, or crashing against hard objects, such as an uneven ground surface.

3.4 | Ilium

The left ilium of ROM 768 bears an abnormal, ventrally elongated pubic peduncle, which overlaps the iliac peduncle of the pubis (Figure 5). Parks (1922) noted the remarkable nature of this feature and, in later studies, it has been referred to for comparison (e.g., Godefroit et al., 2012). The dorsal portion of the elongation seems to have been artificially constructed during restoration of the skeleton, but the section attaching to the pubis, as well as the associated pubic surface, is original. Therefore, it seems unlikely that the elongated feature arose during the preparation or restoration of the skeleton. The pubic peduncles of the ilia in *Parasaurolophus cyrtocristatus* (FMNH P 27393), in the juvenile *Parasaurolophus* sp.

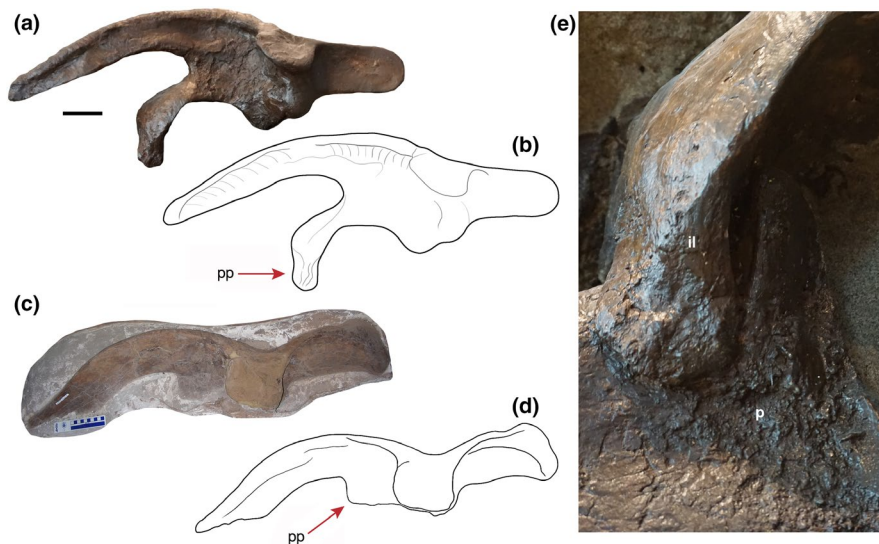


FIGURE 5 (a) Left ilium of ROM 768, with sketch of the same (b); (c) right ilium TMP 1992.053.0021 referred to as cf. *Parasaurolophus* sp., with sketch of the same (d). The picture of the latter specimen and its drawing are mirrored for a better comparison with the left ilium of ROM 768. The red arrows point towards the pubic peduncle of the ilium, which is ventrally elongated in ROM 768 and flat and parallel in TMP 1992.053.0021; (e), close-up of the pathological articular surface in ROM 768 between the abnormally developed pubic peduncle of the ilium and the iliac process of the pubis. Abbreviation: il, ilium; p, pubis; pp, pubic peduncle of the ilium. Scale bar in A and C = 10 cm

(RAM 14000), and in *Charonosaurus jiaynensis* (CUST J-V1251-57) are shorter and less pointed, and similar to *Hypacrosaurus altispinus* (AMNH FARB 5204; Brown, 1913), an indeterminate lambeosaurine MCD 4791 (Prieto-Márquez et al., 2013), *Sahaliyana elunchunorum* (GMH W103; Godefroit et al., 2008), *Corythosaurus casuarius* (AMNH FARB 5240; Brown, 1916), *Barsboldia sicinskii* (ZPAL MgD-I/110; Maryanska & Osmólska, 1981), *Magnapaulia laticaudus* (LACM 20874; Prieto-Márquez et al., 2012), and an indeterminate lambeosaurine MPZ 2005/90 (Prieto-Márquez et al., 2013). In *Olorotitan arharensis* (Godefroit et al., 2012), the pubic peduncle is longer, but not as extended as in ROM 768. Prieto-Márquez (2010) assigns two states for the pubic peduncle morphology in Hadrosauridae: “relatively large and dorsoventrally deep (longer than wide), subconical, with a proximal region that is only slightly craniocaudally wider than the distal end of the process” as the plesiomorphic state and “relatively shorter (wider or as wide as long) and triangular, with a proximal region that is much craniocaudally wider than the distal end” as the derived state. The author scores the derived state for *Parasaurolophus cyrtocristatus* and *Charonosaurus jiaynensis*, but also for *Parasaurolophus walkeri*. The derived morphology is verified in a cf. *Parasaurolophus* sp. ilium from DPP (TMP 1992.053.0021, Figure 5c,d; Prieto-Márquez, pers. comm. 2019). Thus, either the morphology in ROM 768 is due to individual variation or, given the concurrence of injuries in the postcranial skeleton, it is another pathology. The second hypothesis seems to be supported by the nature of the contact surface between the ilium and pubis. The pubic peduncle extends ventrally but, near the point of contact with the distal tip of the iliac peduncle, it develops further curving by approximately 150° and overlapping the lateral side of the iliac peduncle. Here it is pressed over the surface of the latter, forming compressive propagation “waves” on the contact surface (Figure 5e). Usually, in hadrosaurs, pelvic elements are not fused, but rather connected via masses of ligamentous connective tissue (Horner et al., 2004), making the morphology in ROM 768 extremely abnormal. The surface of the overgrowth of the pubic peduncle is slightly rugose, but no evidence of infection or callus formation is evident.

3.5 | Possible etiologies of the pathological lesions

Although the maxillary lesion can probably be regarded as an isolated condition related to oral health status, the pathologies in the postcranial skeleton, while separated physically, may be interconnected to life event(s). The condition associated with the maxillary teeth could have been induced by inflammation (periodontal disease), external trauma, or localized infection. As various hadrosaur species were herding animals (Fiorillo et al., 2014; Hone et al., 2014; Horner et al., 2004; Lockley et al., 1983), injurious conspecific interactions would be expected. A maxillary trauma might have resulted from a lateral impact from a conspecific animal and/or an external object (perhaps, the same incident that caused the injuries in the trunk), or by chewing upon a hard object that damaged soft tissues and (possibly) resulted in a local infection. In living

archosaurs, oral infections occur in the form of osteomyelitis caused by *Staphylococcus aureus*, streptococci, enterococci, *Pseudomonas*, *Enterobacter*, *Proteus*, *Escherichia coli*, *Serratia* and anaerobic bacteria (Huchzermeyer, 2002; Rothschild & Martin, 2006). Once affected by an external agent, the infected area increases in dimension due to elevation of the cortical bone, as seen in ROM 768. In infections, this results in the development of sequestra, bone fragments entrapped within the involucrum (a sheet of granulose tissue) and separated from the original bone. In the maxilla of ROM 768, however, there are no signs of an active infection and drainage channels are absent. The lesion could either be in an advanced state of healing when the individual died (with the bone undergoing the final stages of remodeling, obscuring any evidence of infection) or in an early stage infection. Another explanation is that the alveolar margin of the maxillary dentition was affected by a local inflammation or periodontal disease, generally caused by bacteria in the mouth infecting the tissue around the teeth. Future internal analysis via computerized tomography (CT) scanning will hopefully reveal more information about the definitive nature of the maxillary condition of both ROM 768 and CMN 362.

The injuries in the trunk, both in the dorsal vertebrae and the ribs, are here suggested to have been caused by a single traumatic event. The V-shaped gap, or “saddle” of the dorsal neural spines, appears to have resulted from a vertically directed impact. Furthermore, the succeeding three dorsal neural spines are also angled caudally, which is a different morphology to that observed in other hadrosaurids (e.g., Campione, 2014; Godefroit et al., 2012). This, the possible callus on the prezygapophysis, the V-shaped gap, the abnormal morphology of spine eight with the anterior knob and the anterior slightly concave curvature, and the presence of a discoidal overgrowth on the sixth and seventh dorsal spines together suggest a traumatic cause. However, the shaft of spines seven to

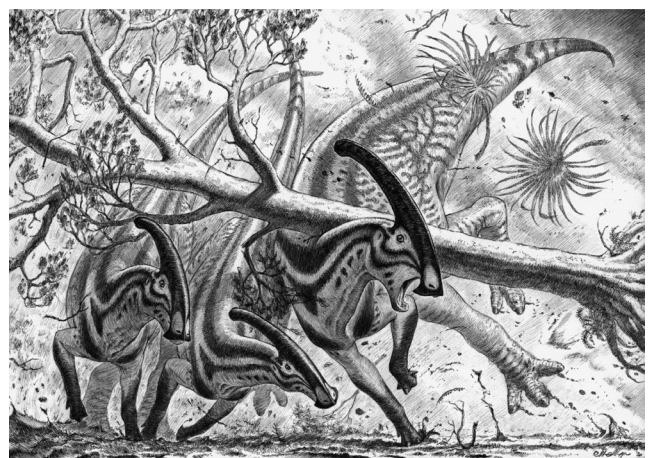

FIGURE 6 Paleoart reconstruction of a plausible scenario explaining the fossilized injuries in the thorax of ROM 768. In a violent rain and windstorm, a large tree (Platanaceae) falls on an adult *Parasaurolophus walkeri*, while the group is escaping. The tree falls vertically on the back of the animal, hitting the rib cage and the neural spines of the anterior dorsal vertebrae. Artwork by Marzio Mereggia

11 do not show abnormal fractures or truncations, except for the slightly swollen lower half of dorsal spines nine, 10 and 11, making the nature of the impact difficult to determine. It could potentially have involved a fallen tree, a large rock, or another animal of similar size and mass, striking vertically or diagonally the trunk of the animal, without causing marked fractures of the spines but rather inducing plastic deformation of the spines in the direct location of the injuries. Another possible explanation is that the strong posterior orientation of dorsal spine eight was caused by the pulling action of the ossified tendons (see below), and the absence of clear fractures in dorsal spine seven is due to a weaker impact than previously assumed. Whatever the cause, the wounded area has undergone advanced healing, which has eliminated some of the finer details of the original injuries. The hypothetical scenario suggested in Figure 6 summarizes the data acquired from the holotype—a large object (here imagined as a tree trunk) fell on the individual, hitting first the lateral side of the trunk, and then the apical region of the back, in line with the fractured ribs. The absence of the “saddle” in the nearly complete skeleton of *Parasaurolophus cyrtocristatus* (Ostrom, 1963) further supports the pathological interpretation of the V-shaped gap in ROM 768.

The abnormal overgrowth of the pubic peduncle of the ilium in ROM 768 is more difficult to diagnose. It could have resulted from a direct blow or, alternatively, was a secondary injury attained because of the difficulties the individual had to endure after the traumatic event as it attempted to regain normal movement. An unusual increase of bone material can be a heterotopic ossification derived from a trauma (myositis ossificans traumatica; Chang et al., 2018; Davies et al., 2017; Kransdorf & Meis, 1993) or a tumoral growth following an injury (i.e., Uda et al., 2002; Urist, 1957). If we assume the abnormal morphology is related to an external trauma, it is possible the anterior region of the ilium might have suffered from the same impact as the thorax, or perhaps a second, separate knock. The absence of any signs of trauma in neighboring elements, such as the pubis itself, the ischium, the femur, and the posterior dorsal vertebrae and their associated ribs, however, makes this suggestion somewhat problematic. The growth of tumoral bone usually happens at the point of injury (see Uda et al., 2002), whereas no reports exist of tumoral masses occurring in a different site following a trauma. In fact, the growth of the peduncle in ROM 768 is limited only to the peduncle itself. The articular point between the ilium and pubis comprises cartilage and, as such, a hypertrophic ossification of the ligamentous connective tissue could have occurred (myositis ossificans traumatica; Kransdorf & Meis, 1993). The implication of this is that a major trauma had resulted in torn muscles/ligaments, possibly as a direct consequence of the impact or perhaps due to the body trying to re-establish a proper balance for locomotion in the subsequent period after the injury. The manner in which the holotype of *P. walkeri* is mounted means that it is not possible to analyse the inner structure of the ilium and, as such, interpretations of the pelvic lesion must remain tentative. Another possible suggestion is a genetic defect but, given the concurrence of injuries on the same side of the body, this seems less likely.

3.6 | Nuchal ligament reconstruction

According to Barkow (1856), in birds the nuchal ligament extends from the dorsal midline in the posterior cervical region and attaches to the dorsal edge of the neural spines, while its anterior most insertion varies across avian taxa. This structure is weakly developed or absent in birds, but is more robust in *Rhea americana*, where it inserts on the neural spine of the axis (Tsuihiji, 2004). Later, the nuchal ligament was also described in *Struthio camelus* (Dzemeski & Christian, 2007). Based on the terminology of Baumel and Raikow (1993), Tsuihiji (2004) refers to the ventrally branched median cervical ligament of *Rhea americana* as *ligamentum elasticum interspinale*, reserving the term *ligamentum nuchae* to the bifurcating ligamentous sheath enclosing it. However, in some avian literature, the non-bifurcated median cervical ligament of other birds is referred to as *ligamentum nuchae* (Barkow, 1856; Yasuda, 2002). A similar, and potentially homologous, median ligamentous structure is also present in non-avian diapsids and inserts to the occiput in *Alligator mississippiensis* and *Iguana iguana* (Tsuihiji, 2004). In other crocodile-related taxa such as dyrosaurids, the supraspinal ligament is considered to have developed into the nuchal ligament, expanding from the anterior thoracic vertebrae to the occipital region of the skull, while ventrally branching onto each of the cervical neural spines (Schwartz-Wings, 2014). The function of the structure is to support and strengthen the neck, by connecting each cervical vertebra in a single contiguous tensile “beam.” The presence of the ligament in dinosaurs has been theorized through the application of extant phylogenetic bracketing (*sensu* Witmer, 1995; Tsuihiji, 2004). In sauropods, the ligament occupies an important point of discussion for the biomechanics of their extremely long and well-developed neck. Based on *R. americana*, Tsuihiji (2004) suggested that the nuchal ligament attached above and to both neural spines of each cervical vertebra (in a branching pattern), originating from the first non-bifurcated dorsal vertebra (dorsal eight) in *Camarasaurus grandis* and on dorsal seven in *Apatosaurus*. Further variations have also been proposed by Schwarz et al. (2007) and Woodruff (2017). In tyrannosaurid theropods, the cervical neural spines are connected through the *M. transversospinalis capitis* (Snively & Russell, 2007), whereas the nuchal ligament (“supraspinal ligament”) would have inserted onto the midline of the supraoccipital (Tsuihiji, 2010). Organ (2006) reconstructed the iguanodontian epaxial musculature following a crocodile model, but he did not discuss the nuchal ligament in ornithopods. In *Parasaurolophus*, the occurrence of the elongated nasal crest has raised questions about the possible presence of such a ligament in the species, and more generally, within hadrosaurids. The crest was a hollow structure, formed internally by three dorsal pairs of tube (median, lateral and dorsal), rising from the external nares to ascend to the tip of the crest where they loop ventrally to return inside the ventral margin of the crest to terminate in a large chamber (Sullivan & Williamson, 1999). Overall, the crest was a relatively light structure but, because of its large size, it probably required a strong and muscular neck. The nuchal ligament was first proposed by Brown (1912) as a means of connecting the anterior dorsal vertebrae

to the base of the neck, while Parks (1922) even suggested it was attached to the distal region of the crest (this last assumption can be discarded since in living archosaurs the ligament attaches to the axis or the occiput). The discoidal overgrowth on the neural spines of dorsal vertebrae six and seven in ROM 768 might be the first osteological correlate to infer the origin site of the nuchal ligament. Both in sauropods (Tsuihiji, 2004) and dyrosaurids (Schwarz-Wings, 2014), the ligament could have originated in the anterior dorsals at the same level as the impact injuries in ROM 768. Woodruff (2017) theorized that, in sauropods, the nuchal ligament (referred to as nuchal ligament and supraspinous ligament altogether in Woodruff (2014)) extended from the occipital region of the cranium to the tail, thereby spanning the entire axial series. In *Parasaurolophus*, and most likely all hadrosaurids, this might not have occurred because of the presence of the overlapping and latticework of ossified epaxial tendons that stiffened the spine from the central and posterior dorsal vertebrae to the mid-caudal vertebrae, perhaps reducing the role of the supraspinal ligament across the axial series. The beginning of the interlaced tendons in the anterior region of the body coincides with the range of the seventh to the ninth dorsal vertebrae in other hadrosaurids. In *Brachylophosaurus canadensis* (MOR 794) the first tendon appears on the third dorsal neural spine, and the number of tendon rods increase to three on the fifth dorsal spine and five on the sixth dorsal spine (Prieto-Márquez, 2007). However, the proper lattice (well visible in *Gryposaurus notabilis* ROM 764; Parks, 1920, pl. 1) begins to form at the caudal portion of the ninth dorsal neural spine (Prieto-Márquez, 2007). In *Prosaurolophus maximus* (ROM 787), ossified tendons start on the fifth dorsal vertebra (Parks, 1924), developing an X-shaped lattice in the more posterior vertebrae. In *Gryposaurus notabilis* (ROM 764, "G.incurvimanus"), insertions of tendons start in dorsal seven and extend to caudal 19, ranging over the entire axial series (Parks, 1920). In *Corythosaurus casuarius* (AMNH 5338), Brown (1916, pg. 712) reports that "[tendons] are developed chiefly overlying the posterior dorsals, sacrals and anterior caudals, diminishing posteriorly and do not appear to have been present toward the distal end of the tail". Based on the skeletal drawings published by Brown (1916, plate XIV, Figure 4), the tendons appear to start on dorsal eight (counting 15 cervical vertebrae starting from the axis). In conclusion, the neural spines where the overlapping lattice of epaxial tendons originate are usually those posterior to dorsals six and seven. These are the same vertebrae (serially) that bear the discoidal shape in ROM 768, thereby enabling a new depiction of the tendon system of hadrosaurids to be determined. The ossified tendons reinforced the dorso-sacro-caudal vertebrae, functioning as a solid and fixed "beam" which could have been adapted for increasing spinal rigidity (Organ, 2006). This would also suggest that the caudal inclination of the three succeeding dorsal spines could have resulted from a "pulling" action of the ossified tendons to counterbalance the spinal rigidity after the traumatic event. On the other hand, the neck necessitated a less rigid structure with a non-ossified, yet strong, fibrous structure such as the nuchal ligament. The position of few, horizontal epaxial ossified tendons in the fifth dorsal vertebra in ROM 787 (Parks, 1924), and

between the third and sixth dorsal spines in *B.canadensis* (Prieto-Márquez, 2007), might suggest that (a) the nuchal ligament and a simple set of ossified tendons coexisted in one, perhaps two consecutive vertebrae, or (b) the origin site of the nuchal ligament differed between hadrosaurid taxa. Further histological analysis on the neural spines of these dorsal vertebrae are needed in future, aided by a possible reexamination of "mummified" specimens.

In summary, it seems possible that the pathological structure that merges the spines of dorsal vertebrae six and seven is a secondary hypertrophic ossification of the base of the nuchal ligament. In humans, trauma can result in a hypertrophic growth of bone material, a benign process characterized by heterotopic ossification usually within large muscles and known as myositis ossificans traumatica. Heterotopic ossification is defined as the formation of bone at atypical sites, in which ectopic lamellar bone forms within a tendon, muscle, or other soft tissue (Chang et al., 2018; Davies et al., 2017; Kransdorf & Meis, 1993). Myositis ossificans traumatica seems to explain the ossification of the discoidal overgrowth on the neural spine, as well as at the pubic peduncle of the ilium (given the absence of internal analysis). Therefore, it seems feasible that the discoidal overgrowth does represent a potential candidate for the first osteological/pathological correlate for the origin site of the *ligamentum nuchae* in hadrosaurids. This strong fibrous structure appears to have originated from the anterior dorsal vertebrae (six or seven), descended over the length of the neck and branched into ventral connections to the cervical neural spines, before finally inserting in the occipital region of the cranium or the axial spine (Figure 7). Ostrom (1961) suggested that in *Corythosaurus casuarius* the nuchal ligament would have attached to the groove rising from the cross bar formed by the supraoccipitals, exoccipitals, opisthotics, and parietals, although in "*Procheneosaurus erectofrons*" (AMNH 5461) the groove is narrower and shorter, likely linked to the young ontogenetic stage of the individual. On the other hand, the anterior half of the axis neural spine in hadrosaurids is generally thickened transversely along its dorsal margin and roughened dorsally, perhaps indicating another possible insertion area for the nuchal ligament (DCE, pers. obs.).

When present in extant tetrapods, the *ligamentum nuchae* (or the homologue) can typically be differentiated into two parts – a long fibrous component corresponding to the dorsal border of the ligament, and a ventrally branched series of fibers or layered fiber bundles that attach to multiple cervical vertebrae. These are referred to as the funicular parts and lamellar (or laminar) parts, respectively, in clinical and veterinary literature (i.e. Bertram & Gellman, 2002; Fielding et al., 1976; Kadri & Al-Mefty, 2007; Mary-Davis & Kleine, 2014). In our reconstruction, we keep a similar structure, although more comparative analyses are required to enable a more definitive and realistic reconstruction. Two different origin sites and two different insertions were considered, based on current knowledge of the location of the nuchal ligament in modern taxa and the myositis ossificans traumatica "shared" between the sixth and seventh neural spines (Figure 7a,c,e,g). Furthermore, we added a second set of reconstructions, reducing the contribution of the lamellar part to the general depth of the neck, since the extension of the lamellar

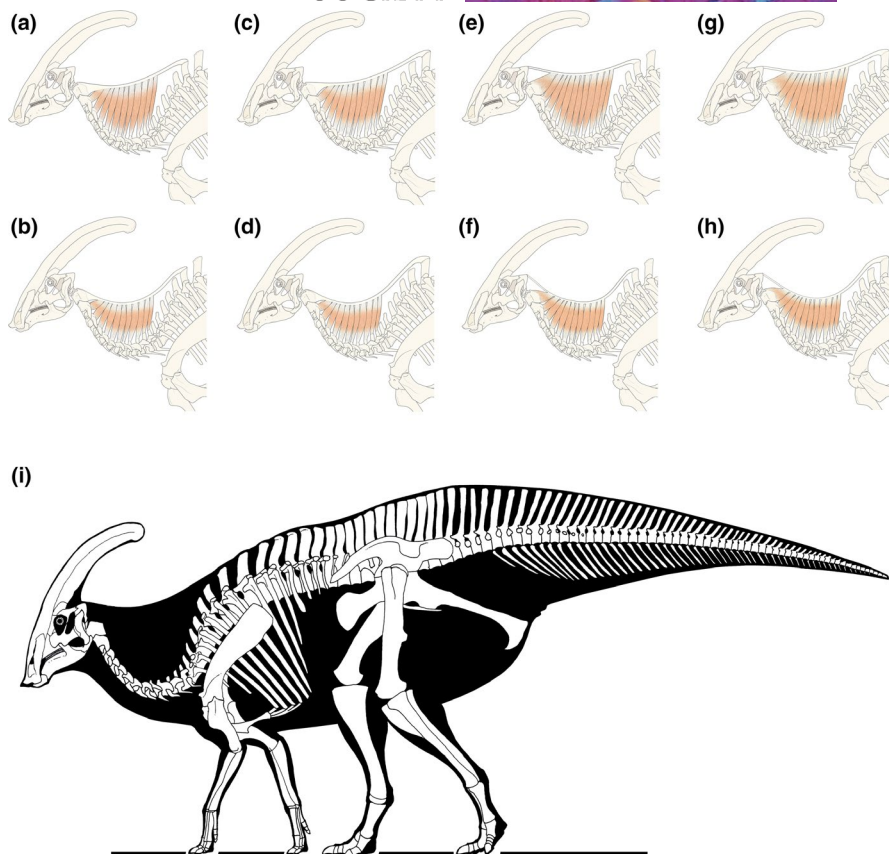


FIGURE 7 Musculoskeletal representation of the nuchal ligament in *Parasaurolophus walkeri*, based on the paleopathological lesions evident in ROM 768, with both long (first row) and short (second row) extension of the lamellar parts. (a,b) the nuchal ligament originates on dorsal six, and attaches to the axis; (c,d) it attaches to the axis while originating on dorsal seven; (e,f) the nuchal ligament originates on dorsal six, and attaches to the occipital region, while in (g,h), it originates from dorsal seven attaching to the occipital region; (i), skeletal reconstruction of *P. walkeri* by Marco Auditore, with the neck depth based on 7e

part varies between closely-related taxa (Figure 7b,d,f,h). Woodruff (2014, fig. 11) showed such variation in the Ankole-Watusi, cow, horse, and giraffe, and it might be linked to the development and elongation of the cervical neural spines. In *Parasaurolophus walkeri*, the anterior cervical spines are low and weakly developed, whereas those in the last five cervicals (thereby next to the cervicodorsal transition) start to elongate, perhaps suggesting a greater contribution of the lamellar sections of the nuchal ligament. A thoughtful quantification and comparison with other hadrosaurids and extant mammals are imperative to better estimate the development of these structures in the future. The resultant thickened neck depth (Figure 7i) corresponds most closely to the morphology illustrated by Gregory S. Paul in recent years (Brett-Surman, 1997) and is in contrast with the initial swan-like neck suggested by traditional authors (i.e. Charles Knight; see below).

3.7 | Paleoart history of *Parasaurolophus*

Consideration of the iconographic history is essential to enable a better understanding of the scientific assumptions and subjective opinions that lay behind recurring “models” (Figure 8). If these are not reviewed *a priori*, continuous misunderstanding can lead to repetitive inaccuracies. Today, *Parasaurolophus* is one of the most famous dinosaurs outside the academic world. Reconstructions of this taxon were rare during the first half of the 20th century, compared to other hadrosaurids, such as *Edmontosaurus*, which is widely

portrayed in books, movies, and exhibitions. Disney's *Fantasia* of 1940 is an important exception, where the representation of *P. walkeri* is based upon the work of Charles Knight and, in particular, a painted scene for the Field Museum in 1931 with an Albertan Campanian vertebrate fauna. In the movie, *Parasaurolophus* has a well-developed skin frill that connects the skull crest to the back, a trait that became popular amongst various illustrators, even today. This reconstruction was based on early research by Barnum Brown. In fact, Brown (1912, pg. 133) advanced that “[in *Saurolophus*] the crest near the posterior end on the dorsal face carries a series of fine ridges and in life it probably bore a frill as in the living lizard *Basiliscus*. This comparison is further borne out by the high spines of the mid-dorsal vertebrae which, like *Basiliscus*, probably carried a high median dorsal frill”. The later discovery of a mummy of *Corythosaurus casuarius* (Brown, 1914; AMNH 5240) strengthened Brown's interpretation. The specimen shows a wide fleshy area that connects the skull to the back, considered as evidence of Brown's (1912) frill. A similar structure was also considered to be present for AMNH 5060 (*Edmontosaurus* mummy; Osborn, 1912), which had preserved skin on the dorsal region of the neck. The area is also characterized by marked skin folds, interpreted by Paul (1987) as natural structures instead of taphonomic artifacts. This consideration helps to understand the point of origin for the *Parasaurolophus* frill, as most of the reconstructions (i.e. by Charles Knight and Gregory Paul) connect the frill to the anterior region of the back, following Parks' ideas. Parks (1922) went even further by assuming a muscular and tendinous connection between the “saddle” and the

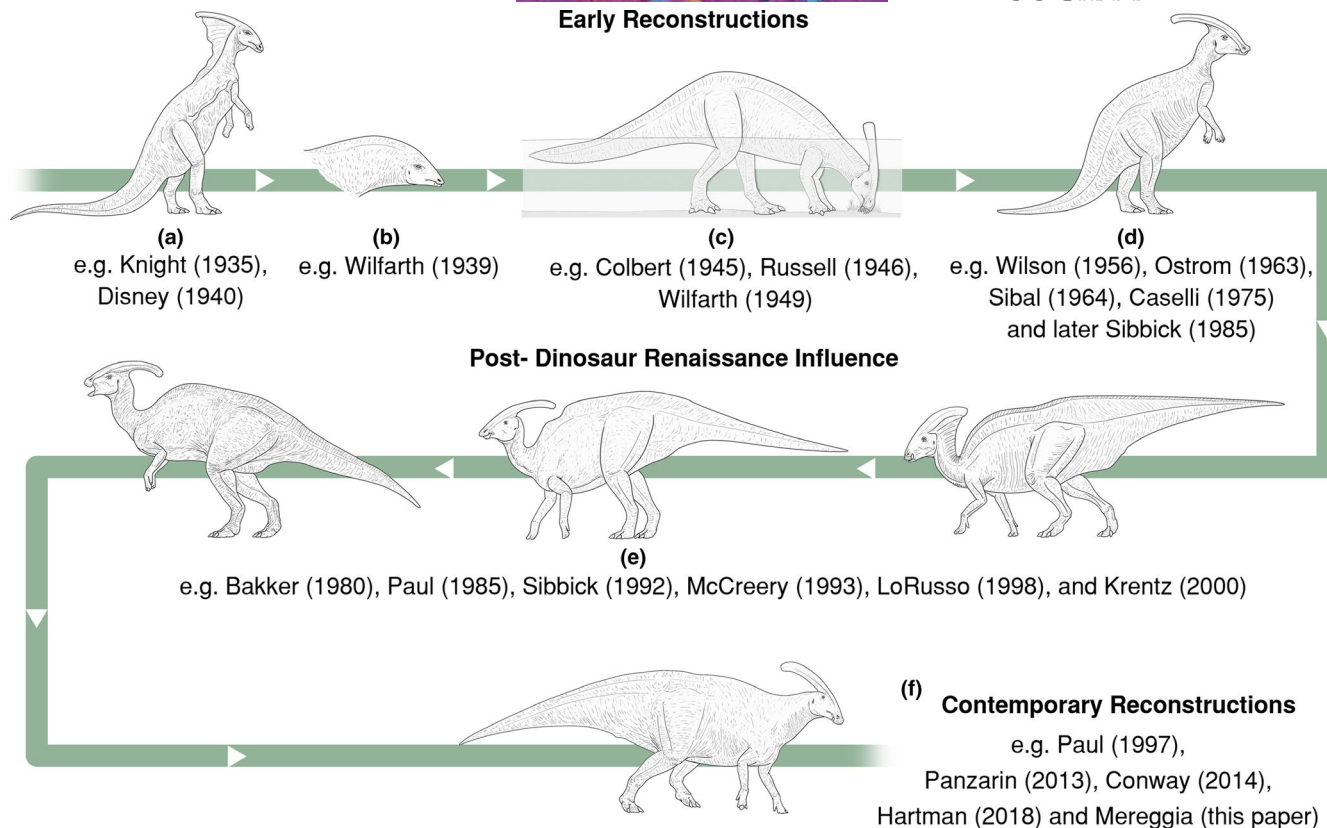


FIGURE 8 “Evolution” of the restorations of *Parasaurolophus* through history, starting from top left. The drawings of each “morphology” represent the general overview of the taxon as understood at that time, together with the external features usually depicted. (a) Knight-influenced: tripodal stance, lizard like anatomy with a large neck frill; (b) crest used as muscular attachment; (c) the aquatic *Parasaurolophus*: the crest is reconstructed as functionally related to aquatic behavior (e.g. air store, water trap or snorkel) for feeding on soft sub-aqueous vegetation; (d) Pre-Dinosaur Renaissance influence: tripodal stance, bulkier anatomy, usually terrestrial, but aquatic depictions still prosper; (e) Post-Dinosaur Renaissance influence: skeletal proportions and overall posture more consistently correct, overly pronated forelimbs, slender anatomy, neck frill and “saddle” variably present; (f) Contemporary reconstructions: bulkier anatomy, thicker neck increasingly common, correctly configured forelimbs and pectoral girdles increasingly common, neck frill and “saddle” generally absent, larger rhamphotheca, speculative soft tissue increasingly common. The years within brackets refer to the year of the published image by the illustrator

caudal-most surface of the crest itself, proposing an extremely wide neck for *Parasaurolophus*. This configuration has since been rejected because of the absence of clear muscle markings on the crest, and the lack of similar features when considering muscle insertion sites in modern Diapsida (Tsuji, 2004). Instead, the crest was believed to serve as a snorkeling structure to facilitate a more amphibious lifestyle (see references in Weishampel, 1981), following the early erroneous reconstructions of hadrosaurids based on the putative “webbed-feet” of the mummies (Osborn, 1912). While the exact details of Parks’ reconstruction do not appear to have been plausible, his appreciation of the importance of cervical musculature seems to correspond well with more contemporary knowledge of terrestrial hadrosaurs.

The previous reconstructions of the frill have drawn attention away from the pathological nature of the discoidal overgrowth and the “saddle”, and perhaps early artists decided to portray a frill to avoid this ambiguous feature. This situation arose despite the fact that Parks (1922) and Lull and Wright (1942) had already suggested that these features in ROM 768 were pathological. Paul (1987)

extended the frill from the crest to the back, whereas Mark Hallett (Wexo, 1985), Luis Rey (Mayes, 1993), John Sibbick (Gardom & Milner, 1993) and Graham Rosewarne (Lambert, 1990) reduced its extension, in a similar manner to that of *Basiliscus plumifrons*. Although the pathological conditions had not been properly analyzed before this study, Paul (1987) proposed a skeletal reconstruction with a modified, normal pattern of dorsal spines – more similar to that of other hadrosaurids – used later for other paleontological illustrations and even for movie productions. The same non-pathological configuration portrayed by Hartman (2020) is largely used as a modern reference since he proposed the same version in 2004. Interestingly, the pathological “saddle” was kept in reconstructions of the taxon without the skin frill (Barrett, 2001; Dixon et al., 1988; Norman, 1985). A case of both “saddle” and skin frill seems to have been presented in the *Parasaurolophus* that appeared in Disney’s *Dinosaur* movie. For the movie, several paleoartists (David Krentz, Mark Hallett, Gregory Paul, Douglas Henderson, and Ricardo Delgado) collaborated, producing one of the best animated models to date, based on the original skeleton with the addition of the *Fantasia*-referenced frill.

The presence of the nuchal ligament and its pathological correlate in ROM 768 highlights another unresolved question – how deep was the neck? Early reconstructions of *Parasaurolophus* and other hadrosaurids depict them with a swan-like, pencil-shaped neck suitable for grazing in an amphibious environment (Figure 8). Czerkas (1993) was the first to suggest the presence of a large nuchal ligament on top of massive neck musculature connected to the first dorsal vertebrae. Paul (Brett-Surman, 1997) shared this interpretation, reconstructing a more bull-like neck in his hadrosaurids, however this was further modified and resized after the discovery of GPDM 115, a *Brachylophosaurus canadensis* “mummy” (Bell, 2014; Murphy et al., 2007). Unfortunately, this mummy has not yet been studied extensively, an unfortunate trend that affects other skin specimens and mummies, which are sometimes only briefly discussed. Hartman (2002) and Ford (2003) proposed an intermediate form that lay in between the swan-like and bull-like neck. In recent years, more provocative and extreme reconstructions have been proposed, such as the “fat” *Parasaurolophus* by Conway (2012), to highlight the range of variability and unpredictability of soft tissue reconstruction. The authors “explore the possibility that [the vertical shoulder folds that cover the upper arm and shoulder region] are actually artifacts of desiccation, and that they supported a heavy padding of fat and muscles in real life” (Conway, 2012, pg. 50). Finally, Bell et al. (2014) reported a mummified specimen of *Edmontosaurus regalis* with preserved fossilized skin and a fleshy cranial crest. Based on the figures provided, the neck looks wide and thick dorsally (as seen in other specimens as well, such as *Corythosaurus casuarius*) perhaps supporting our *Parasaurolophus* reconstruction.

4 | CONCLUSIONS

The holotype of *Parasaurolophus walkeri* is here reported showing several major pathologies: a dental lesion in the left maxilla; myositis ossificans traumatica in the pubic peduncle of the left ilium and in dorsal spines six and seven; a V-shaped gap or “saddle” between dorsal spines seven and eight; and a series of callus formations due to healing simple fractures on three ribs. The lesions evident in *P. walkeri* increase understanding of the pathological bone response to external trauma, adding further data to the expanding knowledge of hadrosaurid paleopathology (Tanke & Rothschild, 2014; Bertozzo et al., in prep). The lesions in ROM 768 appear to have been caused by a single to perhaps three distinct events (maxilla, thorax, pelvis). It is proposed here that the rib and vertebral injuries may have occurred as a result of a large object, such as a tree, falling onto the back of ROM 768, with the pelvic injuries perhaps occurring simultaneously or developing as a secondary response to the initial trauma. It is possible that the dental lesion was also secondary to the trauma although it could equally have occurred in isolation. The injured bones are well remodeled and do not show any signs of ongoing infection. Usually, a callus appears after two-three weeks following the injury (Lovell, 1997; Marsell & Einhorn, 2011), and its resorption is advanced, with progressive obliteration of the fracture line, by the 16th week (Rothschild & Martin, 2006). Since the pathological

lesions were all in an advanced state of healing at the time of death, it seems likely the animal survived for at least one to four months following the traumatic event. The injuries do not appear to have been a direct cause of the animal's death. This finding, together with the increasing observations and reports of paleopathologies in hadrosaurids, might suggest that these dinosaurs were able to overcome and survive such massive injuries. To substantiate this assertion, however, further analysis is required, especially a statistical approach based on remains from large bonebed and museum collections that enable the frequencies of pathological and non-pathological individuals to be determined; such work is already underway (Bertozzo et al., in prep).

The injuries in the spines of dorsal vertebrae six and seven may have corresponded to the original site of the nuchal ligament, a major tendon inserting either on the neural spine of the axis or the occipital region, and likely branching on the cervical neural spines of the neck. It is interesting to note that hadrosaurs and other ornithischians show a complex array of ossified tendons along the vertebral column. The starting point is located posterior to the cervicodorsal transition, but it changes through taxa, as a first line of horizontal tendons, developing into an overlapping X-like pattern generally after dorsal seven, and corresponding to the area posterior to the origin site of the nuchal ligament. This research proposes an indirect osteological correlative for the origin of the nuchal ligament in hadrosaurids, although more in-depth studies are required to confirm this assertion, particularly histological analyses as previously undertaken by Woodruff (2017). The study highlights the necessity of examining complete or near-complete hadrosaurid skeletons, with the cervicodorsal transition preserved, to confirm the origin of this important structure. This would enable more insights to be gained concerning the biomechanics of hadrosaurids and other ornithischians.

ACKNOWLEDGEMENTS

We thank Shino Sugimoto and the staff of the ROM for the help provided during the study of the holotype of *Parasaurolophus*. We are grateful to Dr. Caleb Brown (TMP), and Brandon Strilisky (TMP) for access to the pathological ribs in the TMP collection, and a special thanks are due to the staff of the TMP for the help provided during the study. We thank Dr. Jordan Mallon (CMN) and the staff of CMN for providing access and help to study the ornithopod bone collection, especially CMN 362. Information about hadrosaur anatomy and muscular structure have been discussed with Dr. Albert Prieto-Márquez (Institut Català de Paleontologia Miquel Crusafort, Sabadell, Spain), who also provided comparative pictures, and Dr. Simone Maganuco (Museo di Storia Naturale, Milan, Italy). We thank Marzio Mereggi (Accademia di Belle Arti, Bologna, Italy) for the wonderful in-vivo reconstruction of the *Parasaurolophus* herd (Figure 6), and Marco Auditore for the skeletal reconstruction in Figure 7i. The project was partially funded by the 2018 Dinosaur Research Institute Student Project (Alberta, Canada), and it is part of FB's doctoral dissertation within the Horizon 2020 research and innovation programme under the MSCA grant agreement no 754507. All the

authors confirm there are not conflicts of interest to disclose. We are grateful to the reviewers Cary Woodruff (GPDM, ROM) and Dr. Elizabeth Freedman-Fowler (Badlands Dinosaur Museum, Dickinson Museum Center, Dickinson, North Dakota) who provided valuable comments and suggestions for the improvement of this paper.

AUTHORS' CONTRIBUTION

FB conceived and designed the study; DCE gave access to the main specimen; FB acquired and analyzed the data; interpretation of results and implications were performed and discussed by all authors; FB and MD drafted the figures; FB, FM, EM, DHT and MD drafted the manuscript; all authors revised the manuscript and provided final approval before submission.

DATA AVAILABILITY STATEMENT

Data sharing not applicable to this article as no datasets were generated or analysed during the current study

ORCID

Filippo Bertozzo  <https://orcid.org/0000-0002-0917-9989>

REFERENCES

- Anné, J., Hedrick, B.P. & Schein, J.P. (2016) First diagnosis of septic arthritis in a dinosaur. *Royal Society Open Science*, 3, 160222.
- Anné, J., Russell, J.G., Tristan, L., Withers, P.J. & Manning, P.L. (2015) Interpreting pathologies in extant and extinct archosaurs using Micro-CT. *PeerJ*, 3, e1130.
- Barbosa, F.H.S., da Costa Ribeiro, I., da Costa Pereira, P.V.L.G. & Paglarelli Bergqvist, L. (2018) Vertebral lesions in a titanosaurian dinosaur from the Lower-Upper Cretaceous of Brazil. *Geobios*, 51, 385–389.
- Barbosa, F.H.S., Pereira, P.V.L.G.C., Bergqvist, L.P., & Rothschild, B.M. (2016) Multiple neoplasms in a single sauropod dinosaur from the Upper Cretaceous of Brazil. *Cretaceous Research*, 62, 13–17.
- Barkow, H.C.L. (1856) *Syndesmologie Der Vögel*. Konighlichen Universitat, Nischkowsky.
- Barrett, P.M. (2001). *National geographic dinosaurs*. National Geographic Children's Books, 1–192.
- Baumel, J.J. & Raikow, R.J. (1993) *Arthrologia*. In: Baumel, J.J., King, A.S., Breazile, J.E., Evans, H.E. & Vanden Berge, J.C. (Eds.) *Handbook of avian anatomy: Nomina anatomica avium*. Cambridge, MA: Nuttall Ornithological Club, pp. 133–187.
- Bell, P.R. (2014) A review of hadrosaurid skin impressions. In: Eberth, D.A. & Evans, D.C. (Eds.) *Hadrosaurs*. Bloomington, IN: Indiana University Press, pp. 572–590.
- Bell, P.R., Fanti, F., Currie, P.J. & Arbour, V.M. (2014) A mummified duck-billed dinosaur with a soft-tissue cock's comb. *Current Biology*, 24, 70–75.
- Bertozzo, F., Dal Sasso, C., Fabbri, M., Manucci, F. & Maganuco, S. (2017) Redescription of a remarkably large *Gryposaurus notabilis* (Dinosauria: Hadrosauridae) from Alberta, Canada. *Società Italiana di Scienze Naturali e Museo Civico di Storia Naturale, Milano*, XLIII, 1–56.
- Bertram, J.E.A. & Gellman, K.S. (2002) The equine nuchal ligament 1: structural and material properties. *Veterinary and Comparative Orthopaedics and Traumatology*, 15, 01–06.
- Brett-Surman, M.K. (1997) Ornithopods. In: Farlow, J.O. & Brett-Surman, M.K. (Eds.) *The Complete Dinosaur*. Bloomington, IN: Indiana University Press, pp. 330–346.
- Brown, B. (1912) A crested dinosaur from the Edmonton Cretaceous. *Bulletin of the American Museum of Natural History*, 31, 131–136.
- Brown, B. (1913) A new trachodont dinosaur, *Hypacrosaurus*, from the Edmonton Cretaceous of Alberta. *Bulletin of the American Museum of Natural History*, 32, 395–406.
- Brown, B. (1914) *Corythosaurus casuarius*, a new crested dinosaur from the Belly River Cretaceous, with provisional classification of the family Trachodontidae. *Bulletin of the American Museum of Natural History*, 33, 559–565.
- Brown, B. (1916) *Corythosaurus casuarius*: Skeleton, musculature and epidermis. *Bulletin of the American Museum of Natural History*, 35, 709–716.
- Campione, N.E. (2014) Postcranial anatomy of *Edmontosaurus regalis* (Hadrosauridae) from the Horseshoe Canyon Formation, Alberta, Canada. In: Eberth, D.A. & Evans, D.C. (Eds.) *Hadrosaurs*. Bloomington, IN: Indiana University Press, pp. 208–244.
- Chang, S.H., Matsumoto, T., Okajima, K., Naito, M., Hirose, J. & Tanaka, S. (2018) Heterotopic ossification of the peroneus longus tendon in the retromalleolar portion with the peroneus quartus muscle: a case report. *Case Reports in Orthopedics*, 2018, 1–5.
- Conway, J., Kosemen, C.M. & Naish, D. (2012) *All Yesterdays: unique and speculative views of dinosaurs and other prehistoric animals*. lulu.com.
- Czerkas, S.A. (1993) Frills and goosenecks. *Journal of Vertebrate Paleontology*, 13(Supplement 3), 32A.
- Davies, O.G., Liu, Y., Player, D.J., Martin, N.R.W., Grover, L.M. & Lewis, M.P. (2017) Defining the balance between regeneration and pathological ossification in skeletal muscle following traumatic injury. *Frontiers in Physiology*, 8, 194.
- Dixon, D., Cox, B., Savage, R.J.G. & Gardine, B. (1988) *The MacMillan illustrated encyclopedia of dinosaurs and prehistoric animals: A visual who's who of prehistoric life*. London, UK: Macmillan London Limited, pp. 1–312.
- Dzemeski, G. & Christian, A. (2007) Flexibility along the neck of the ostrich (*Struthio camelus*) and consequences for the reconstruction of dinosaurs with extreme neck length. *Journal of Morphology*, 268, 701–714.
- Ekhtiari, S., Chiba, K., Popovic, S., Crowther, R., Wohl, G., Wong, A.K.O. et al. (2020) First case of osteosarcoma in a dinosaur: a multimodal diagnosis. *The Lancet. Oncology*, 21, 1021–1022.
- Evans, D.C. (2006) Nasal cavity homologies and cranial crest function in lambeosaurine dinosaurs. *Paleobiology*, 32, 109–125.
- Evans, D.C., Bavington, R. & Campione, N.E. (2009) An unusual hadrosaurid braincase from the Dinosaur Park Formation and the biostratigraphy of *Parasaurolophus* (Ornithischia: Lambeosaurinae) from southern Alberta. *Canadian Journal of Earth Sciences*, 46, 791–800.
- Evans, D.C., Reisz, R.R. & Dupuis, K. (2007) A juvenile *Parasaurolophus* (Ornithischia: Hadrosauridae) braincase from Dinosaur Provincial Park, Alberta, with comments on crest ontogeny in the genus. *Journal of Vertebrate Paleontology*, 27, 642–650.
- Farke, A.A., Chok, D.J., Herrero, A., Scolieri, B. & Werning, S. (2013) Ontogeny in the tube-crested dinosaur *Parasaurolophus* (Hadrosauridae) and heterochrony in hadrosaurids. *PeerJ*, 1, e182.
- Fielding, J.W., Burstein, A.H. & Frankel, V.H. (1976) The nuchal ligament. *Spine*, 1, 3–14.
- Fiorillo, A.R., Hasiotis, S.T. & Kobayashi, Y. (2014) Herd structure in Late Cretaceous polar dinosaurs: a remarkable new dinosaur tracksite, Denali National Park, Alaska, USA. *Geology*, 2, 719–722.
- Ford, T.L. (2003) How to draw dinosaurs. Pencil necked hadrosaurs?. *Prehistoric Times*, 61, 14.
- Gardom, T. & Milner, A.C. (1993) *The Natural History Museum book of dinosaurs*, 1st edition, London, UK: Virgin Books, pp. 1–128.
- Gates, T.A., Lund, E.K., Boyd, C.A., DeBlieux, D.D., Titus, A.L., Evans, D.C. et al. (2013) Ornithopod dinosaurs from the Grand Staircase-Escalante National Monument Region, Utah, and their role in paleobiogeographic and macroevolutionary studies. In: Titus, A.L. & Loewen, M.A. (Eds.) *At the top of the Grand Staircase: the Late*

- Cretaceous in Utah. Bloomington, IN: Indiana University Press, pp. 463–481.
- Godefroit, P., Bolotsky, Y.L. & Bolotsky, I.Y. (2012) Osteology and relationships of *Olorotitan arharensis*, a hollow-crested hadrosaurid dinosaur from the latest Cretaceous of Far Eastern Russia. *Acta Palaeontologica Polonica*, 57, 527–560.
- Godefroit, P., Shulin, H., Tingxiang, Y. & Lauters, P. (2008) New hadrosaurid dinosaurs from the uppermost Cretaceous of Northeastern China. 2008. *Acta Palaeontologica Polonica*, 53, 47–74.
- Hartman, S. (2002) Estimating nuchal ligament depth in hadrosaurid dinosaurs: the return of the pencil-necked hadrosaurs?. Tate 2002 Field Conference Guide.
- Hartman, S. (2020) Available at: <https://www.skeletaldrawing.com/>. [Accessed May–June 2020].
- Hedrick, B.P., Gao, C., Tumarkin-Deratzian, A.R., Shen, C., Holloway, J.L., Zhang, F. et al. (2016) An injured *Psittacosaurus* (Dinosauria: Ceratopsia) from the Yixian Formation (Liaoning, China): implications for *Psittacosaurus* biology. *The Anatomical Record*, 299, 897–906.
- Hone, D.W., Sullivan, C., Zhao, Q., Wang, K. & Xu, X. (2014) Body size distribution in a death assemblage of a colossal hadrosaurid from the Upper Cretaceous of Zhucheng, Shandong Province, China. In: Eberth, D.A. & Evans, D.C. (Eds.) *Hadrosaurs*. Bloomington, IN: Indiana University Press, pp. 524–553.
- Horner, J.R., Weishampel, D.B. & Forster, C.A. (2004) Hadrosauridae. In: Weishampel, D.B., Osmólska, H. & Dodson, P. (Eds.) *The Dinosauria*, 2nd edition, Berkeley, CA: University of California Press, pp. 438–563.
- Huchzermeyer, F.W. (2002) Diseases of farmed crocodiles and ostriches. *Revue Scientifique et Technique-Office International Des Epizooties*, 21, 265–276.
- Hunt, T.C., Peterson, J.E., Frederickson, J.A., Cohen, J.E. & Berry, J.L. (2019) First documented pathologies in *Tenontosaurus tilletti* with comments on infection in non-avian dinosaurs. *Scientific Reports*, 9, 1–8.
- Jentgen-Ceschino, B., Stein, K. & Fischer, V. (2020) Case study of radial fibrolamellar bone tissues in the outer cortex of basal sauropods. *Philosophical Transactions of the Royal Society B*, 375, 20190143.
- Kadri, P.A. & Al-Mefty, O. (2007) Anatomy of the nuchal ligament and its surgical applications. *Operative Neurosurgery*, 61(Supplement5), ONS301-ONS304.
- Kransdorf, M.J. & Meis, J.M. (1993) Extraskelatal osseous and cartilaginous tumors of the extremities. *Radiographics*, 13, 853–884.
- Lambert, D. (1990) *The dinosaur data book facts and fictions about the world's largest creatures*. The Diagram Group. New York: Avon Books, pp. 1–320.
- Lockley, M.G., Young, B.H. & Carpenter, K. (1983) Hadrosaur locomotion and herding behavior: Evidence from footprints in the Mesaverde Formation, Grand Mesa Coal Field, Colorado. *Mountain Geologist*, 20, 5–14.
- Lovell, N.C. (1997) Trauma analysis in paleopathology. *Yearbook of Physical Anthropology*, 40, 139–170.
- Lull, R.S. & Wright, N.E. (1942) Hadrosaurian dinosaurs of North America. *Geological Society of America Special Papers*, 40, 1–272.
- Marsell, R. & Einhorn, T.A. (2011) The biology of fracture healing. *Injury*, 42, 551–555.
- Maryanska, T. & Osmólska, H. (1981) First lambeosaurine dinosaur from the Nemegt Formation, Upper Cretaceous, Mongolia. *Acta Palaeontologica Polonica*, 26, 243–255.
- May-Davis, S. & Kleine, J. (2014) Variations and implications of the gross anatomy in the equine nuchal ligament lamellae. *Journal of Equine Veterinary Science*, 34, 1110–1113.
- Mayes, S. (1993) *The Usborne book of dinosaurs*. London, UK: Usborne Publishing Ltd, pp. 1–32.
- Molnar, R.E. (2001) Theropod paleopathology: a literature survey. In: Tanke, D.H. & Carpenter, K. (Eds.) *Mesozoic vertebrate life*. Bloomington, IN: Indiana University Press, pp. 337–363.
- Moodie, R.L. (1923) *Paleopathology: An introduction to the study of ancient evidences of disease*. Champaign, IL: University of Illinois Press, pp. 1–894.
- Murphy, N.L., Trexler, D. & Thompson, M. (2007) “Leonardo”, a mummified *Brachylophosaurus* (Ornithischia: Hadrosauridae) from the Judith River Formation of Montana. In: Carpenter, K. (Ed.) *Horns and Beaks. Ceratopsian and Ornithopod Dinosaurs*. Bloomington, IN: Indiana University Press, pp. 117–134.
- Naish, D. (2008) Pads and notches in the necks of tube-crested hadrosaurs. SAY WHAT?. Available at: <https://scienceblogs.com/tetrapodzoology/2008/09/11/tube-crested-hadrosaur-neck>. [Accessed May–June 2020].
- Norman, D.B. (1985) *The illustrated encyclopedia of dinosaurs*. London, UK: Salamander Books, pp. 1–208.
- Organ, C.L. (2006) Biomechanics of ossified tendons in ornithopod dinosaurs. *Paleobiology*, 32, 652–665.
- Osborn, H.F. (1912) Integument of the iguanodont dinosaur *Trachodon*. *American Museum of Natural History Memoir Part*, II, 33–54.
- Ostrom, J.H. (1961) A new species of hadrosaurian dinosaur from the Cretaceous of New Mexico. *Journal of Paleontology*, 35, 575–577.
- Ostrom, J.H. (1962) The cranial crests of hadrosaurian dinosaurs. *Yale Peabody Museum of Natural History Postilla*, 88, 1–35.
- Ostrom, J.H. (1963) *Parasaurolophus cyrtocristatus*, a crested hadrosaurian dinosaur from New Mexico. *Fieldiana*, 14, 143–168.
- Parks, W.A. (1920) Osteology of the trachodont dinosaur *Kritosaurus incurvimanus*. *Toronto The University Library*, 11, 1–74.
- Parks, W.A. (1922) *Parasaurolophus walkeri* a new genus and species of crested trachodont dinosaur. *Toronto The University Library*, 13, 1–32.
- Parks, W.A. (1924) *Dyoplosaurus Acutosquameus*: a new genus and species of armoured dinosaur; and notes on a skeleton of *Prosaurolophus maximus*. *Toronto The University Library*, 18, 1–35.
- Paul, G.S. (1987) The science and art of restoring the life appearance of dinosaurs and their relatives. *Dinosaurs Past and Present*, 2, 5–49.
- Prieto-Márquez, A. (2007) Postcranial osteology of the hadrosaurid dinosaur *Brachylophosaurus canadensis* from the Late Cretaceous of Montana. In: Carpenter, K. (Ed.) *Horns and beaks. Ceratopsian and ornithopod dinosaurs*. Bloomington, IN: Indiana University Press, pp. 91–115.
- Prieto-Márquez, A. (2010) Global historical biogeography of hadrosaurid dinosaurs. *Zoological Journal of the Linnean Society*, 159, 503–525.
- Prieto-Márquez, A., Chiappe, L.M. & Joshi, S.H. (2012) The lambeosaurine dinosaur *Magnapaulia laticaudus* from the Late Cretaceous of Baja California, Northwestern Mexico. *PLoS One*, 7, e38207.
- Prieto-Márquez, A., Dalla Vecchia, F.M., Gaete, R. & Galobart, À. (2013) Diversity, relationships, and biogeography of the lambeosaurine dinosaurs from the European Archipelago, with description of the new aralosaurin *Canardia garonnensis*. *PLoS One*, 8, e69835.
- Redelstorff, R., Hayashi, S., Rothschild, B.M. & Chinsamy, A. (2015) Non-traumatic bone infection in *Stegosaurus* from Como Bluff, Wyoming. *Lethaia*, 48, 47–55.
- Rothschild, B.M. & Martin, L.D. (2006) Skeletal impact of disease. *New Mexico Museum of Natural History and Science*, 33, 1–226.
- Rothschild, B.M., Tanke, D.H., Helbling, M. & Martin, L.D. (2003) Epidemiologic study of tumors in dinosaurs. *Naturwissenschaften*, 90, 495–500.
- Russell, L.S. (1946) The crest of the dinosaur *Parasaurolophus*. *Contribution of the Royal Ontario Museum of Palaeontology*, 2, 1–5.
- Ryan, M.J. & Evans, D.C. (2005) Ornithischian dinosaurs. In: Currie, P.J. & Koppelhus, E.B. (Eds.) *Dinosaur Provincial Park. A spectacular ancient ecosystem revealed*. Bloomington, IN: Indiana University Press, pp. 312–348.
- Schwarz, D., Frey, E. & Meyer, C.A. (2007) Pneumaticity and soft-tissue reconstructions in the neck of diplodocid and dicraeosaurid sauropods. *Acta Palaeontologica Polonica*, 52, 167–188.

- Schwarz-Wings, D. (2014) The feeding apparatus of dyrosaurids (Crocodyliformes). *Geological Magazine*, 151, 144–166.
- Senter, P. & Juengst, S.L. (2016) Record-breaking pain: the largest number and variety of forelimb bone maladies in a theropod dinosaur. *PLoS One*, 11, e0149140.
- Siviero, B.C., Rega, E., Hayes, W.K., Cooper, A.M., Brand, L.R. & Chadwick, A.V. (2020) Skeletal trauma with implications for intratril mobility in *Edmontosaurus annectens* from a monodominant bonebed, Lance Formation (Maastrichtian), Wyoming USA. *Palaios*, 35, 201–214.
- Snively, E. & Russell, A.P. (2007) Functional variation of neck muscles and their relation to feeding style in Tyrannosauridae and other large theropod dinosaurs. *The Anatomical Record: Advances in Integrative Anatomy and Evolutionary Biology*, 290, 934–957.
- Sullivan, R.M. & Williamson, T.E. (1999) A new skull of *Parasaurolophus* (Dinosauria: Hadrosauridae) from the Kirtland Formation of New Mexico and a revision of the genus. *New Mexico Museum of Natural History and Science Bulletin*, 15, 1–52.
- Tanke, D.H. & Rothschild, B.M. (2002) DINOSORES: An annotated bibliography of dinosaur paleopathology and related topics—1838–2001. *New Mexico Museum of Natural History and Science Bulletin*, 20.
- Tanke, D.H. & Rothschild, B.M. (2014) Paleopathology in Late Cretaceous hadrosauridae from Alberta, Canada. In: Eberth, D.A. & Evans, D.C. (Eds.) *Hadrosaurs*. Bloomington, IN: Indiana University Press, pp. 540–571.
- Tsuihiji, T. (2004) The ligament system in the neck of *Rhea americana* and its implication for the bifurcated neural spines of sauropod dinosaurs. *Journal of Vertebrate Paleontology*, 24, 165–172.
- Tsuihiji, T. (2010) Reconstructions of the axial muscle insertions in the occipital region of dinosaurs: evaluations of past hypotheses on Marginocephalia and Tyrannosauridae using the Extant Phylogenetic Bracket approach. *The Anatomical Record: Advances in Integrative Anatomy and Evolutionary Biology*, 293, 1360–1386.
- Uda, H., Mizuzeki, T. & Tsuge, K. (2002) Osteoid osteoma of the metacarpal bone presenting after an injury. *Scandinavian Journal of Plastic and Reconstructive Surgery and Hand Surgery*, 36, 238–242.
- Urist, M.R. (1957) Trauma and neoplasm: Report of case of desmoid tumor following simple fracture of the radius and ulna. *The American Journal of Surgery*, 93, 682–693.
- Weishampel, D.B. (1981) Acoustic analyses of potential vocalization in lambeosaurine dinosaurs (Reptilia: Ornithischia). *Paleobiology*, 7, 252–261.
- Wexo, J.B. (1985) *Zoobooks: Dinosaurs*. Santee, CA, USA: Zoobooks/Wildlife Education, pp. 1–18.
- Wiman, C. (1931) *Parasaurolophus tubicen* n. Sp. Aus Der Kreide in New Mexico. *Nova Acta Regiae Societatis Scientiarum Upsaliensis*, 4, 1–19.
- Witmer, L.M. (1995) The extant phylogenetic bracket and the importance of reconstructing soft tissues in fossils. *Functional Morphology in Vertebrate Paleontology*, 1, 19–33.
- Woodruff, D.C. (2014) The anatomy of the bifurcated neural spine and its occurrence within Tetrapoda. *Journal of Morphology*, 275, 1053–1065.
- Woodruff, D.C. (2017) Nuchal ligament reconstructions in diplodocid sauropods support horizontal neck feeding postures. *Historical Biology*, 29, 308–319.
- Yasuda, M. (2002) *The anatomical atlas of Gallus*. Tokyo: University of Tokyo Press, pp. 1–445.

How to cite this article: Bertozzo F, Manucci F, Dempsey M, et al. Description and etiology of paleopathological lesions in the type specimen of *Parasaurolophus walkeri* (Dinosauria: Hadrosauridae), with proposed reconstructions of the nuchal ligament. *J Anat.* 2020;00:1–15. <https://doi.org/10.1111/joa.13363>