



**QUEEN'S
UNIVERSITY
BELFAST**

Axial postural abnormalities in parkinsonism: gaps in predictors, pathophysiology, and management

Geroïn, C., Artusi, C. A., Nonnekes, J., Aquino, C., Garg, D., Dale, M. L., Schlosser, D., Lai, Y., Al-Wardat, M., Salari, M., Wolke, R., Labou, V. T., Imbalzano, G., Camozzi, S., Merello, M., Bloem, B. R., Capato, T., Djaldetti, R., Doherty, K., ... the International Parkinson and Movement Disorders Society Task Force on Postural Abnormalities (2023). Axial postural abnormalities in parkinsonism: gaps in predictors, pathophysiology, and management. *Movement Disorders*, 38(5), 732-739. <https://doi.org/10.1002/mds.29377>

Published in:

Movement Disorders

Document Version:

Publisher's PDF, also known as Version of record

Queen's University Belfast - Research Portal:

[Link to publication record in Queen's University Belfast Research Portal](#)

Publisher rights

Copyright 2023 the authors.

This is an open access article published under a Creative Commons Attribution-NonCommercial-NoDerivs License

(<https://creativecommons.org/licenses/by-nc-nd/4.0/>), which permits distribution and reproduction for non-commercial purposes, provided the author and source are cited.

General rights

Copyright for the publications made accessible via the Queen's University Belfast Research Portal is retained by the author(s) and / or other copyright owners and it is a condition of accessing these publications that users recognise and abide by the legal requirements associated with these rights.

Take down policy

The Research Portal is Queen's institutional repository that provides access to Queen's research output. Every effort has been made to ensure that content in the Research Portal does not infringe any person's rights, or applicable UK laws. If you discover content in the Research Portal that you believe breaches copyright or violates any law, please contact openaccess@qub.ac.uk.

Open Access

This research has been made openly available by Queen's academics and its Open Research team. We would love to hear how access to this research benefits you. – Share your feedback with us: <http://go.qub.ac.uk/oa-feedback>

Axial Postural Abnormalities in Parkinsonism: Gaps in Predictors, Pathophysiology, and Management

Christian Geroin, PhD,^{1*} Carlo Alberto Artusi, MD, PhD,² Jorik Nonnekes, MD, PhD,³ Camila Aquino, MD, PhD,⁴ Divyani Garg, MD, DM, DNB, MNAMS,^{5,6} Marian L. Dale, MD, MRC,⁷ Darbe Schlosser,⁸ Yijie Lai, MD,⁹ Mohammad Al-Wardat, PT, PhD,¹⁰ Mehri Salari, MD, PhD,¹¹ Robin Wolke, MD,¹² Valery Tsinda Labou, PhD,¹³ Gabriele Imbalzano, MD,² Serena Camozzi, PT,¹ Marcelo Merello, MD, PhD,¹⁴ Bastiaan R. Bloem, MD, PhD,¹⁵ Tamine Capato, PhD,^{15,16} Ruth Djaldetti, MD,¹⁷ Karen Doherty, MD, FRCP,^{18,19} Alfonso Fasano, MD, PhD,^{20,21,22} Houyam Tibar, MD,²³ Leonardo Lopiano, MD, PhD,^{2,24} Nils G. Margraf, MD, PhD,¹² Caroline Moreau, MD, PhD,²⁵ Yoshikazu Ugawa, MD, PhD,²⁶ Roongroj Bhidayasiri, MD, FRCP,^{27,28} and Michele Tinazzi, MD, PhD,^{1*} on behalf of the International Parkinson and Movement Disorders Society Task Force on Postural Abnormalities

¹Neurology Unit, Movement Disorders Division, Department of Neurosciences Biomedicine and Movement Sciences, University of Verona, Verona, Italy

²Department of Neuroscience Rita Levi Montalcini, University of Turin, Torino, Italy

³Department of Rehabilitation, Radboud University Medical Centre, Donders Institute for Brain, Cognition and Behaviour, Nijmegen, The Netherlands

⁴Department of Clinical Neurosciences, and Department of Community Health Sciences, Hotchkiss Brain Institute, University of Calgary, Calgary, Alberta, Canada

⁵Department of Neurology, Lady Hardinge Medical College, New Delhi, India

⁶Department of Neurology, Vardhman Mahavir Medical College and Safdarjung Hospital, New Delhi, India

⁷Department of Neurology, Oregon Health and Science University, Portland, Oregon, USA

⁸Motor Learning Program, Teachers College, Columbia University, New York, New York, USA

⁹Department of Neurosurgery, Center for Functional Neurosurgery, Ruijin Hospital, Shanghai Jiao Tong University School of Medicine, Shanghai, China

¹⁰Department of Rehabilitation Sciences, Faculty of Applied Medical Sciences, Jordan University of Science and Technology, Irbid, Jordan

¹¹Department of Neurology, Shahid Beheshti University of Medical Sciences, Tehran, Iran

¹²Department of Neurology, UKSH, Christian-Albrechts-University, Kiel, Germany

¹³Neurorehabilitation and Movement Disorders Society, Yaoundé, Cameroon

¹⁴Movement Disorders Service, FLENI, CONICET, Buenos Aires, Argentina

¹⁵Department of Neurology, Radboud University Medical Centre, Donders Institute for Brain, Cognition and Behaviour, Nijmegen, The Netherlands

¹⁶Department of Neurology, Movement Disorders Center, University of São Paulo, São Paulo, Brazil

¹⁷Department of Neurology, Rabin Medical Center, Petah Tikva Sackler Faculty of Medicine, Tel Aviv University, Tel Aviv, Israel

¹⁸Department of Neurology, Royal Victoria Hospital, Belfast, UK

¹⁹Centre for Medical Education, Queens University Belfast, Belfast, UK

²⁰Krembil Brain Institute, Toronto, Ontario, Canada

²¹Edmond J. Safra Program in Parkinson's Disease, Morton and Gloria Shulman Movement Disorders Clinic, Toronto Western Hospital, UHN, Toronto, Ontario, Canada

²²Division of Neurology, University of Toronto, Toronto, Ontario, Canada

²³Service de Neurologie B et de Neurogénétique Hôpital des Spécialités OTO-Neuro-Ophtalmologique, Ibn Sina University Hospital, Medical School of Rabat, Mohamed 5 University of Rabat, Rabat, Morocco

²⁴Neurology 2 Unit, A.O.U. Città della Salute e della Scienza di Torino, Torino, Italy

²⁵Neurological Department, Expert Center for Parkinson's Disease, Inserm UMR 1172, Lille University Hospital, Lille, France

© 2023 The Authors. *Movement Disorders* published by Wiley Periodicals LLC on behalf of International Parkinson and Movement Disorder Society.

This is an open access article under the terms of the [Creative Commons Attribution-NonCommercial-NoDerivs](#) License, which permits use and distribution in any medium, provided the original work is properly cited, the use is non-commercial and no modifications or adaptations are made.

Key Words: postural abnormalities, Pisa syndrome, camptocormia, antecollis, parkinsonism, clinical predictors, pathophysiology

***Correspondence to:** Prof. Michele Tinazzi, Neurology Unit, Movement Disorders Division, Department of Neurosciences, Biomedicine and Movement Sciences, University of Verona, P.le Scuro 10, 37134 Verona, Italy; E-mail: michele.tinazzi@univr.it Dr. Christian Geroin, Neurology

Unit, Movement Disorders Division, Department of Neurosciences, Biomedicine and Movement Sciences, University of Verona, P.le Scuro 10, 37134 Verona, Italy; E-mail: christian.geroin@univr.it

Christian Geroin and Carlo Alberto Artusi contributed equally to this work.

Relevant conflicts of interest/financial disclosures: Nothing to report.

Funding agency: Open Access Funding provided by Università degli Studi di Verona within the CRUI-CARE Agreement.

Received: 24 October 2022; **Revised:** 14 February 2023; **Accepted:** 17 February 2023

Published online 20 April 2023 in Wiley Online Library (wileyonlinelibrary.com). DOI: 10.1002/mds.29377

²⁶Department of Human Neurophysiology, School of Medicine, Fukushima Medical University, Fukushima, Japan

²⁷Department of Medicine, Faculty of Medicine, Chulalongkorn Centre of Excellence for Parkinson's Disease and Related Disorders, Chulalongkorn University and King Chulalongkorn Memorial Hospital, Thai Red Cross Society, Bangkok, Thailand

²⁸The Academy of Science, The Royal Society of Thailand, Bangkok, Thailand

Axial postural abnormalities are common and disabling motor complications of Parkinson's disease (PD) and parkinsonism. They consist of abnormal trunk or neck postures in the upright position, often interfering with daily life activities.¹⁻⁵

A high number of patients with PD may develop one or more axial postural abnormalities, which may begin as minor forms, almost universal in persons with parkinsonism (eg, minor flexed posture of the trunk and lower limbs), and progress to severe forms such as camptocormia, antecollis, or Pisa syndrome in over 20% of patients,¹ although the definitions of severe axial postural abnormalities were purely based on subjective/expert opinion. Drug-induced parkinsonism or progressive supranuclear palsy may also present axial postural abnormalities, and in multiple system atrophy these symptoms are more frequent than in PD and occur earlier in the disease course.^{2,6} Because axial postural abnormalities are associated with an increased risk of falling, pain, and diminished quality of life, their proper prevention and management is warranted.^{2,4,5,7,8} However, to date, recommendations for multidisciplinary management and prevention remain an unmet need.³ Diagnosis is typically based on a simple clinical examination, whereas treatments (eg, pharmacological, physical therapy, and surgical treatments) have been evaluated only in small single-center studies that failed to show consistent, long-lasting improvement.^{2,5,8-10} The absence of reliable protocols for the assessment, treatment, and prevention of axial postural abnormalities in parkinsonism is probably due to the largely obscure pathophysiology and uncertainty about prognostic factors needed to estimate beneficial responses to therapy (eg, duration of axial postural abnormalities).^{2,5,8,11-13} The aim of this viewpoint is to critically analyze the literature on axial postural abnormalities, identify the current issues and gaps, and formulate proposals for current clinical management and future research exploration.

The Problems Identified

Issues and Gaps Regarding Clinical Predictors

Research on clinical predictors and risk factors for the onset of axial postural abnormalities in parkinsonism was mainly limited by the low quality of the methodology in the available literature (Supporting Information).^{2,5,8} Indeed, only a few studies were aimed primarily at the analysis of risk factors, and most studies were cross-sectional, lacking adequate longitudinal

follow-up. In most cases the patient sample (usually PD) was heterogeneous for disease severity and stage.

Clinical predictors were investigated for all axial postural abnormalities; however, the dependent variable in many studies was the presence of more than one axial postural abnormality, rather than a singular one. This approach renders it difficult to identify clinical predictors specific for each axial postural abnormality, which may vary between camptocormia, Pisa syndrome, and antecollis. Also, the cutoffs defining an axial postural abnormality differed across studies and were not stated in many cases. This generated possible bias in the prevalence rates due to differences in the clinical characteristics of patient samples. The identification of clinical predictors in patient samples presenting different degrees of trunk/neck flexion is challenging and limits interpretation of the study results. For example, patients with greater trunk flexion may also have more motor complications (ie, motor fluctuations) that make it difficult to identify the clinical predictors for mild axial forms (ie, anterior trunk flexion),³ which are of major clinical interest for prevention strategies. Finally, the variability in tools and reference bone points used for quantifying the degree of axial postural abnormalities renders comparison of study results arduous.

Issues and Gaps in Pathophysiology

The pathophysiology of axial postural abnormalities in PD is not clear, but several causes have been proposed,^{2,5,8} including central mechanisms (eg, imbalance in basal ganglia functioning leading to dystonia/rigidity, altered sensory-motor integration, higher cognitive function deficits) and/or peripheral mechanisms (ie, alteration in the musculoskeletal system).^{2,5,8} The main pathophysiological mechanisms considered in the literature are discussed here (Supporting Information).

Hypertonia: Dystonia and Rigidity

Dystonia, or a more general hyperactivity of paraspinal and nonparaspinal muscles, is the most common explanation for axial disability based on findings from electromyographic investigation.^{2,5,8,9,14-20} The hypothesis that dystonia underlies axial postural abnormalities is supported by three main findings: (1) the existence of drug-induced Pisa syndrome or camptocormia, (2) the (rare) existence of sensory tricks to alleviate some postural abnormalities, and (3) evidence of misalignment improvement by botulinum toxin type-A or lidocaine administration in some patients.^{2,5,8}

However, in patients with Pisa syndrome, electromyography findings have been inconsistent concerning the side (ipsilateral or contralateral) of hyperactivity of paraspinal and nonparaspinal muscles in relation to trunk bending and PD asymmetry.^{16,18,19} Some studies suggested two different electromyographical patterns: (1) hyperactivity of lumbar and thoracic paraspinals ipsilateral to the trunk-leaning side during quiet stance and voluntary contralateral trunk flexion^{18,21} and (2) hyperactivity of nonparaspinal muscles (eg, external oblique muscles, rectus femoris, and iliopsoas) ipsilaterally to the leaning side during quiet stance and during voluntary contralateral trunk flexion.¹⁷ The paraspinal muscles contralateral to the side of flexion may have a compensatory action to further limit trunk bending.¹⁷ Other studies reported tonic and persistent activity in the paraspinal thoracic muscle and/or abdominal oblique muscles ipsilateral to the bending side and less-affected PD side, along with reduced/absent activity of the same muscles on the opposite side.¹⁹

In patients with camptocormia, studies suggested that the bilateral abdominal internal and the external oblique muscles, together with the rectus abdominis muscles, may be responsible for camptocormia with thoracic fulcrum,¹⁴ whereas rectus abdominis and iliopsoas hyperactivity could be more frequently involved in camptocormia with lumbar fulcrum.^{14,20} Another study found hyperactivity of paraspinal muscles (ie, iliocostalis lumborum, longissimus, and multifidus) and, to a lesser extent, the rectus femoris but not rectus abdominis.¹⁵ It is probable that some hyperactivities observed in camptocormia, like those of paraspinal muscles that are spine erectors, are compensatory.

Patients with antecollis showed hypertrophy and active spasms or hyperactivity in anterior (sternocleidomastoid muscles) and posterior (semispinalis, splenius capitis, trapezius, and levator scapulae) neck muscles.² Passive head-up maneuvers may be limited by marked bilateral contractions of sternocleidomastoid muscles.²

The paucity of studies and objective measures to identify and quantify dystonia complicates the interpretation of these findings. Needle electromyography (EMG) has limited use because it is invasive and can be challenging when applied in deep muscles. Also, interpretation of needle EMG is relatively subjective as it is technically difficult to perform and has not been standardized for investigating axial muscles, and quantitative normative measures for activation of these muscle groups are not available. Finally, when EMG is performed in those with long-standing symptoms, it remains difficult to reliably separate primary abnormalities (ie, those causing postural abnormalities) from secondary ones (ie, resulting from the chronic changes in posture, or related to compensatory mechanisms).

No studies have specifically and systematically evaluated rigidity in patients with axial postural abnormalities. During clinical examination in the supine position,

patients demonstrate almost complete resolution of trunk bending, whereas when sitting or standing the paravertebral muscles may appear to have a wooden consistency.^{2,15} The association between axial postural abnormalities and a more severe motor impairment and a rigid-akinetic phenotype makes rigidity a process worthy of investigation, albeit difficult to measure it empirically.

Impaired Proprioception, Kinesthesia, and Cognitive Deficits

Patients with PD have difficulty in properly controlling their postural stabilization and orientation (and also their interaction) based on sensory information from muscles and joints.² PD patients with Pisa syndrome or camptocormia find it more difficult to achieve good postural alignment with gravity and display greater velocity of body sway than patients without axial postural abnormalities.^{22,23} Patients with camptocormia with a lower fulcrum may have more severe gait and postural control deficits than patients with a thoracic fulcrum or patients without camptocormia.²³ However, no studies have so far investigated the relationship between antecollis and postural instability. Postural control is a complex system involving the integration of different sensory inputs, including vestibular, visual, and proprioceptive. Some findings support the notion that proprioceptive function/kinesthesia is abnormal in PD.^{22,23} Evidence was initially restricted to motor control of the limbs,²⁴ but more recent studies^{22,23} showed that proprioceptive defects might also affect axial motor control not only in the yaw plane (turning about the vertical axis)²⁴ but also in the sagittal and coronal planes. Further studies are needed to understand the contribution of defective proprioceptive and kinesthesia in the pathophysiology of axial postural abnormalities.^{2,24}

Moreover, postural control depends on vestibular information. PD patients with Pisa syndrome may present with a central, peripheral, or mixed vestibular dysfunction² along with a deviation in the subjective visual vertical,²⁵ which was estimated to occur in about 67% of PD patients.²⁶ A recent case-control study found worse performance on visuospatial ability tasks by PD patients with Pisa syndrome compared to PD controls without axial postural abnormalities.²⁷ Visuospatial deficits are associated with dysfunctional subjective visual vertical, possibly contributing to altered perception of the trunk in space and the development of Pisa syndrome but not camptocormia.²⁷ Whether visual spatial deficits and subjective visual vertical are defective and might also contribute to the development of antecollis has not been systematically investigated yet. Moreover, postural control demands complex motor-cognitive interactions that rely on high attentional

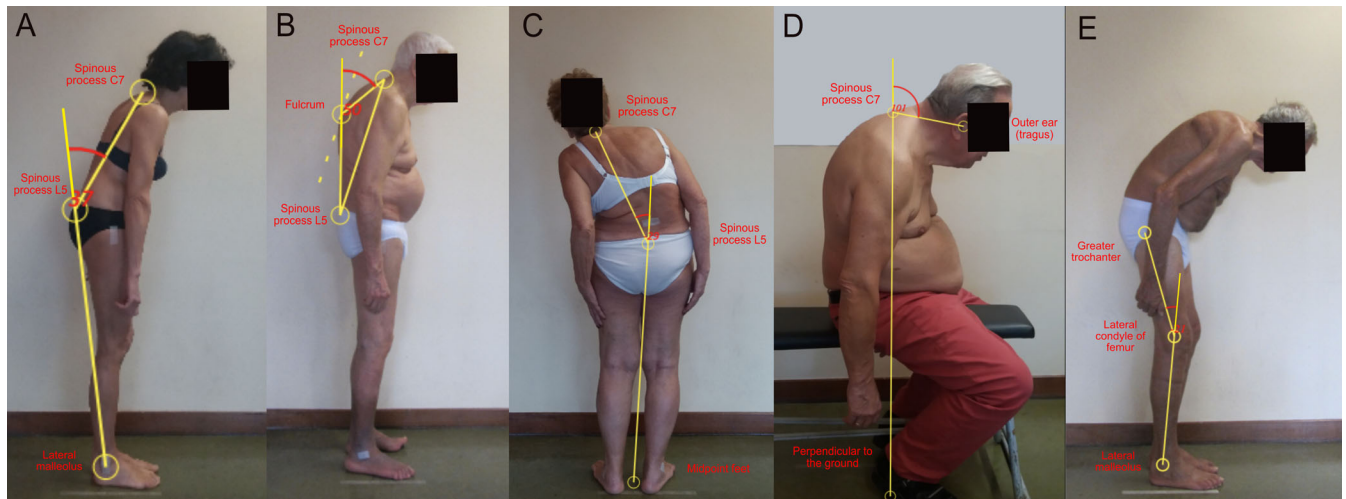


FIG. 1. The consensus recommendation is to measure (A) camptocormia (lateral fulcrum) angle using the malleolus method; (B) camptocormia (thoracic fulcrum) angle using the upper method; and (C) the Pisa syndrome angle and (D) the antecollis angle using the perpendicular method. Thoracic and lumbar camptocormia should be evaluated with the patient standing in a relaxed position without external supports. Antecollis should be evaluated with the patient seated in a chair without armrests and external supports. Their back should be kept straight to measure the contribution of cervical tract to antecollis, without compensation of the thoracic and the lumbar spine. Besides the degree of trunk flexion, knee angles should be evaluated because of coexisting postural misalignments (E). Images should be taken horizontally from a distance of at least 3 m from the patient with the lens approximately at waist height. The image should display the patient fully filling the screen. We recommend calculating posture degrees by analyzing images with the measurements proposed in the NeuroPostureApp, a freeware software-based tool (<https://www.neuroimaging.uni-kiel.de/NeuroPostureApp>).⁴⁰ [Color figure can be viewed at wileyonlinelibrary.com]

resources and conserved executive functions. Some studies reported lower scores on tasks exploring executive functions (ie, divided attention, inhibitory control, and delayed free recall in verbal learning), perceptual visuospatial functions, and language for patients with Pisa syndrome compared to patients with PD without axial postural abnormalities.^{2,5,8,28} Nevertheless, the association between kinesthetic/proprioceptive and cognitive deficits with axial postural abnormalities remains controversial. Without further details from pathophysiology studies, and also without intervention studies, three possibilities remain: (1) these deficits are a mere association (ie, they merely coincide with those with more severe disease), (2) these dysfunctions are not causal but rather a secondary manifestation (ie, they result as a consequence of the axial postural abnormalities), or (3) they are actually a contributing factor.

Myopathy and Weakness

The bulk of evidence from EMG (eg, fibrillation potentials, small polyphasic motor unit potentials, and weakness),^{5,8,14,15,17,19,29-34} muscle biopsy (eg, abnormal histology),^{5,8,29-32,35} and muscle imaging (eg, fatty infiltration of muscles and muscle atrophy)^{5,8,9,14,17,19,29-31,36} suggests myopathy as a contributing factor to the development of axial postural abnormalities. The cause of myopathy remains unclear, but ongoing research marks it as a secondary myopathic process, as a consequence of a chronically maintained abnormal posture.³⁴ These phenomena probably reflect a continuum from early

myopathic changes (ie, edema and partial swelling, contrast enhancement without degenerative muscle changes) in the early stages of camptocormia to progression to muscle atrophy and fatty degeneration in the end stage as shown by muscle magnetic resonance imaging (MRI) and biopsy. Although the exact cause of these muscular changes is unclear, they may arise due to muscle disuse or denervation secondary to chronic primary trunk misalignment. Camptocormia might be a consequence of overusing paraspinal muscles due to rigidity in patients with PD or a pronounced proprioceptive dysregulation in the context of underlying disease. Although a primary myopathy has been suggested to explain Pisa syndrome,¹⁹ no pathological studies have proven this hypothesis. Therefore, the observed muscular changes are probably caused by secondary mechanisms. The atrophy of paraspinal muscles ipsilateral to the bending side may be due to muscle disuse (excluded because of hyperactivity of nonparaspinal muscles) and cannot contribute to the development of Pisa syndrome; contralateral muscle atrophy instead might be secondary to the stress of prolonged stretching, as a consequence of muscle weakness, theoretically leading to Pisa syndrome.¹⁷ The mechanical efficiency of muscular activation of trunk extension (especially at the thoracic level) was markedly reduced in PD patients with camptocormia compared to those with PD without postural issues and to healthy controls, which suggests impairment of neuromuscular recruitment.³⁴

The EMG of the paraspinal muscles is technically difficult, but this disadvantage is relative, as MRI and muscle biopsy can show the presence of myopathy.

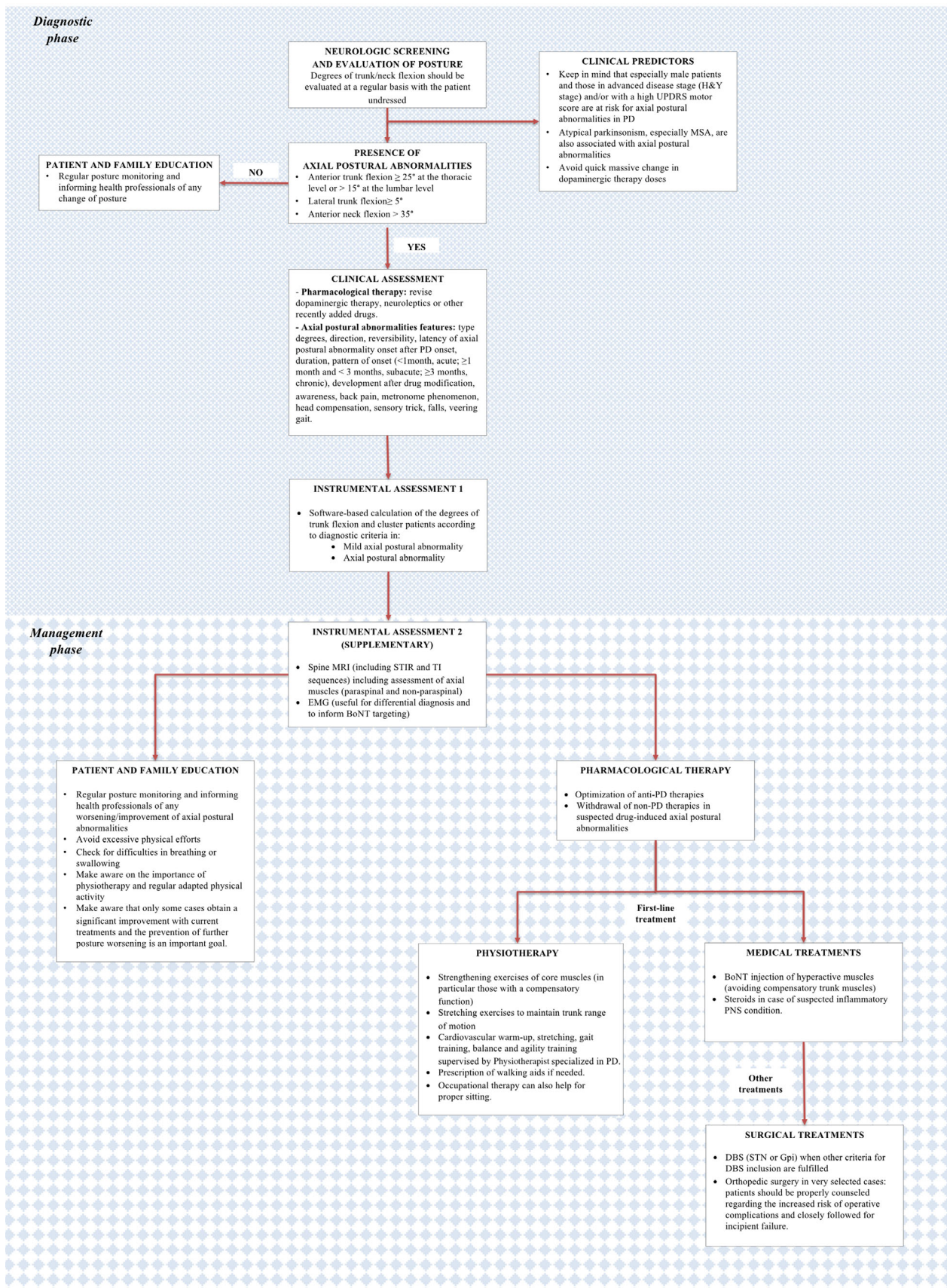


FIG. 2. Legend on next page.

Although the finding of a monomorphic myopathy in the camptocormia of PD patients can be considered corroborated,³⁵ the clarification of its cause remains an important task. Currently, the recording of myopathy with its subdivision into acute and chronic forms of muscle changes provides clues for therapeutic options.¹²

Other Findings

Postural improvement after high-frequency deep brain stimulation (DBS) of the bilateral subthalamic nuclei³⁷ supports the notion that axial postural abnormalities may result from dysfunction of the basal ganglia. There is limited evidence for the presence of drug-induced axial postural abnormalities in persons with parkinsonism,^{2,5,8} with a dose reduction (or even complete withdrawal) or switching to another dopaminergic medication leading to improvement in posture.^{2,8,38} Finally, patients with axial postural abnormalities may present with a concomitant clinical history of back surgery (eg, laminectomy), degenerative spinal conditions, or trauma, which may have mechanical effects on bones or soft tissue (eg, muscles or fascia) and predisposing to their development.³⁹

Proposals for Current Clinical Management

In clinical practice, the first step is to objectively measure the degree of trunk and/or neck flexion preferably while the patient is wearing only underwear (Fig. 1) during standing and walking.⁴⁰ We suggest to investigate the possible presence of mild forms of axial postural abnormalities at each visit and inform and educate patients and caregivers on these symptoms; when actual axial postural abnormalities have been identified, clinicians could consider pharmacological and nonpharmacological interventions for their treatment. Figure 2 shows a practical road map as guidance for their clinical management.

Proposals for Future Research Exploration

Four major issues may have limited the progress of research in this field: (1) different nosology and cutoffs to define axial postural abnormalities, (2) lack of common

and objective assessment procedures, (3) heterogeneity of study design, and (4) heterogeneity of patient samples.

Future research should focus on their clinical evaluation in terms of early detection and quantification using consensus-based criteria.³ Prospective, observational, long-term studies with large samples are immediately needed to explore the potential risk (causal) factors and pathophysiology involved in their development. From a therapeutic point of view, we call for well-controlled clinical trials: randomized trials using standard criteria for inclusion and endpoint measurement³ are needed to compare the efficacy of different pharmacological and non-pharmacological interventions and their combined effect (ie, botulinum toxin injections + physiotherapy). Such controlled studies could also focus on the merits of dopaminergic therapy withdrawal when these are suspected to have played a role in causing axial postural abnormalities. Moreover, we suggest researchers focus on a single postural abnormality per study, because risk factors, pathophysiology, and response to treatments may vary between camptocormia, Pisa syndrome, and antecollis. Finally, prevention programs using common diagnostic criteria³ should be investigated to study how the development of axial postural abnormalities can be avoided.

Educate patients and their families to monitor possible improvement or worsening of posture.

Adjustment of pharmacological therapy: remove the prescribed dopaminergic therapy potentially associated with the subacute onset of axial postural abnormality. The removal of therapy needs to be done very cautiously as this may also lead to a worsening of the underlying parkinsonism.⁸

Other expert opinion-based options include the following: botulinum toxin injection of hyperactive muscles should be cautiously considered for each patient based on EMG findings, in carefully selected patients, under the care of experts; avoiding injections of compensatory paraspinal and nonparaspinal muscles; prompt physiotherapy intervention to strengthen weak/compensatory trunk/neck muscles and improve balance and mobility; and prescription of walking aids (ie, high-frame walker) if needed. When a patient is suitable for DBS aimed at managing motor symptoms, camptocormia, and Pisa syndrome could also improve after surgery. Orthopedic surgery should be considered in very selected cases: patients should be properly counseled regarding the increased risk of operative complications and closely followed for incipient failure. ■

FIG. 2. Expert opinion-based flowchart of axial postural abnormality management. (1) Diagnostic phase: screening and assessment of axial postural abnormalities, including examination of body posture and software-based measurement of even small degrees of trunk and neck flexion. (2) Management phase: electromyographic evaluation (static and dynamic) of axial muscle activity, motor unit potential analysis, and MRI (magnetic resonance imaging) of the paraspinal and nonparaspinal muscles (eg, STIR and T1 sequences) could be additional exams supporting the management. These exams could be employed to evaluate the presence of axial muscle dystonic or myopathic features and spinal and soft tissue changes and to rule out alternative or coexisting diseases. [Color figure can be viewed at wileyonlinelibrary.com]

Acknowledgment: We thank Rossella Targa (librarian) for her assistance in developing the literature search strategy. Open Access Funding provided by Università degli Studi di Verona within the CRUI-CARE Agreement.

Data Availability Statement

Data sharing not applicable to this article as no datasets were generated or analysed during the current study

References

- Tinazzi M, Gandolfi M, Ceravolo R, et al. Postural abnormalities in Parkinson's disease: an epidemiological and clinical multicenter study. *Mov Disord Clin Pract* 2019;6(7):576–585.
- Doherty KM, van de Warrenburg BP, Peralta MC, et al. Postural deformities in Parkinson's disease. *Lancet Neurol* 2011;10(6):538–549.
- Tinazzi M, Geroïn C, Bhidayasiri R, et al. Task force consensus on nosology and cut-off values for axial postural abnormalities in parkinsonism. *Mov Disord Clin Practice* 2022;9(5):594–603.
- Margraf NG, Granert O, Hampel J, Wrede A, Schulz-Schaeffer WJ, Deuschl G. Clinical definition of camptocormia in Parkinson's disease. *Mov Disord Clin Pract* 2017;4(3):349–357.
- Srivanitchapoom P, Hallett M. Camptocormia in Parkinson's disease: definition, epidemiology, pathogenesis and treatment modalities. *J Neurol Neurosurg Psychiatry* 2016;87(1):75–85.
- Ashour R, Jankovic J. Joint and skeletal deformities in Parkinson's disease, multiple system atrophy, and progressive supranuclear palsy. *Mov Disord* 2006;21(11):1856–1863.
- Geroïn C, Artusi CA, Gandolfi M, et al. Does the degree of trunk bending predict patient disability, motor impairment, falls, and Back pain in Parkinson's disease? *Front Neurol* 2020;11:207.
- Tinazzi M, Geroïn C, Gandolfi M, et al. Pisa syndrome in Parkinson's disease: an integrated approach from pathophysiology to management. *Mov Disord* 2016;31(12):1785–1795.
- Artusi CA, Bortolani S, Merola A, et al. Botulinum toxin for Pisa syndrome: an MRI-, ultrasound- and electromyography-guided pilot study. *Parkinsonism Relat Disord* 2019;62:231–235.
- Gandolfi M, Tinazzi M, Magrinelli F, et al. Four-week trunk-specific exercise program decreases forward trunk flexion in Parkinson's disease: a single-blinded, randomized controlled trial. *Movement Disord* 2019;34:S263.
- Schulz-Schaeffer WJ. Camptocormia in Parkinson's disease: a muscle disease due to dysregulated proprioceptive polysynaptic reflex arch. *Front Aging Neurosci* 2016;8:128.
- Margraf NG, Wrede A, Deuschl G, Schulz-Schaeffer WJ. Pathophysiological concepts and treatment of camptocormia. *J Parkinsons Dis* 2016;6(3):485–501.
- Schulz-Schaeffer WJ, Margraf NG, Munser S, et al. Effect of neurostimulation on camptocormia in Parkinson's disease depends on symptom duration. *Mov Disord* 2015;30(3):368–372.
- Magrinelli F, Geroïn C, Squintani G, et al. Upper camptocormia in Parkinson's disease: neurophysiological and imaging findings of both central and peripheral pathophysiological mechanisms. *Parkinsonism Relat D* 2020;71:28–34.
- Margraf NG, Rogalski M, Deuschl G, Kuhtz-Buschbeck JP. Trunk muscle activation pattern in parkinsonian camptocormia as revealed with surface electromyography. *Parkinsonism Relat Disord* 2017;44:44–50.
- Geroïn C, Squintani G, Morini A, et al. Pisa syndrome in Parkinson's disease: electromyographic quantification of paraspinal and non-paraspinal muscle activity. *Funct Neurol* 2017;32(3):143–151.
- Tinazzi M, Juergenson I, Squintani G, et al. Pisa syndrome in Parkinson's disease: an electrophysiological and imaging study. *J Neurol* 2013;260(8):2138–2148.
- Di Matteo A, Fasano A, Squintani G, et al. Lateral trunk flexion in Parkinson's disease: EMG features disclose two different underlying pathophysiological mechanisms. *J Neurol* 2011;258(5):740–745.
- Tassorelli C, Furnari A, Buscone S, et al. Pisa syndrome in Parkinson's disease: clinical, electromyographic, and radiological characterization. *Mov Disord* 2012;27(2):227–235.
- Furusawa Y, Hanakawa T, Mukai Y, et al. Mechanism of camptocormia in Parkinson's disease analyzed by tilt table-EMG recording. *Parkinsonism Relat Disord* 2015;21(7):765–770.
- Fasano A, Di Matteo A, Vitale C, et al. Reversible Pisa syndrome in patients with Parkinson's disease on rasagiline therapy. *Mov Disord* 2011;26(14):2578–2580.
- Geroïn C, Smania N, Schena F, et al. Does the Pisa syndrome affect postural control, balance, and gait in patients with Parkinson's disease? An observational cross-sectional study. *Parkinsonism Relat Disord* 2015;21(7):736–741.
- Geroïn C, Gandolfi M, Maddalena I, Smania N, Tinazzi M. Do upper and lower Camptocormias affect gait and postural control in patients with Parkinson's disease? An observational cross-sectional study. *Parkinsons Dis* 2019;2019:9026890.
- Carpenter MG, Bloem BR. Postural control in Parkinson patients: a proprioceptive problem? *Exp Neurol* 2011;227(1):26–30.
- Mikami K, Shiraishi M, Kamo T. Effect of subjective vertical perception on lateral flexion posture of patients with Parkinson's disease. *Sci Rep* 2022;12(1):1532.
- Gandor F, Basta D, Gruber D, Poewe W, Ebersbach G. Subjective visual vertical in PD patients with lateral trunk flexion. *Parkinsons Dis* 2016;2016:7489105.
- Artusi CA, Montanaro E, Erro R, et al. Visuospatial deficits are associated with Pisa syndrome and not camptocormia in Parkinson's disease. *Mov Disord Clin Pract* 2022;10(1):64–73.
- Artusi CA, Montanaro E, Tuttobene S, Romagnolo A, Zibetti M, Lopiano L. Pisa syndrome in Parkinson's disease is associated with specific cognitive alterations. *Front Neurol* 2019;10:577.
- Schabitz WR, Glatz K, Schuhan C, et al. Severe forward flexion of the trunk in Parkinson's disease: focal myopathy of the paraspinal muscles mimicking camptocormia. *Mov Disord* 2003;18(4):408–414.
- Margraf NG, Wrede A, Rohr A, et al. Camptocormia in idiopathic Parkinson's disease: a focal myopathy of the paravertebral muscles. *Mov Disord* 2010;25(5):542–551.
- Spuler S, Krug H, Klein C, et al. Myopathy causing camptocormia in idiopathic Parkinson's disease: a multidisciplinary approach. *Mov Disord* 2010;25(5):552–559.
- Wanschitz JV, Sawires M, Seppi K, et al. Axial myopathy in parkinsonism. *Mov Disord* 2011;26(8):1569–1571.
- Savica R, Kumar N, Ahlskog JE, Josephs KA, Matsumoto JY, McKeon A. Parkinsonism and dropped head: dystonia, myopathy or both? *Parkinsonism Relat Disord* 2012;18(1):30–34.
- Wolke R, Kuhtz-Buschbeck JP, Deuschl G, Margraf NG. Insufficiency of trunk extension and impaired control of muscle force in Parkinson's disease with camptocormia. *Clin Neurophysiol* 2020;131(11):2621–2629.
- Wrede A, Margraf NG, Goebel HH, Deuschl G, Schulz-Schaeffer WJ. Myofibrillar disorganization characterizes myopathy of camptocormia in Parkinson's disease. *Acta Neuropathol* 2012;123(3):419–432.
- Margraf NG, Rohr A, Granert O, Hampel J, Drews A, Deuschl G. MRI of lumbar trunk muscles in patients with Parkinson's disease and camptocormia. *J Neurol* 2015;262(7):1655–1664.
- Lizarraga KJ, Fasano A. Effects of deep brain stimulation on postural trunk deformities: a systematic review. *Mov Disord Clin Pract* 2019;6(8):627–638.
- Tinazzi M, Fasano A, Geroïn C, et al. Pisa syndrome in Parkinson disease: an observational multicenter Italian study. *Neurology* 2015;85(20):1769–1779.

39. Tiple D, Fabbri G, Colosimo C, et al. Camptocormia in Parkinson disease: an epidemiological and clinical study. *J Neurol Neurosurg Psychiatry* 2009;80(2):145–148.
40. Margraf NG, Wolke R, Granert O, et al. Consensus for the measurement of the camptocormia angle in the standing patient. *Parkinsonism Relat Disord* 2018;52:1–5.

Supporting Data

Additional Supporting Information may be found in the online version of this article at the publisher's web-site.