



**QUEEN'S
UNIVERSITY
BELFAST**

Curiositas: Medical student quiz

Hamilton, P., & Corr, M. (2016). Curiositas: Medical student quiz. *The Ulster Medical Journal*, 85(1), 55-56.
[https://www.ums.ac.uk/umj085/085\(1\)055.pdf](https://www.ums.ac.uk/umj085/085(1)055.pdf)

Published in:
The Ulster Medical Journal

Document Version:
Publisher's PDF, also known as Version of record

Queen's University Belfast - Research Portal:
[Link to publication record in Queen's University Belfast Research Portal](#)

Publisher rights
© 2015 Ulster Medical Journal.
This work is made available online in accordance with the publisher's policies. Please refer to any applicable terms of use of the publisher

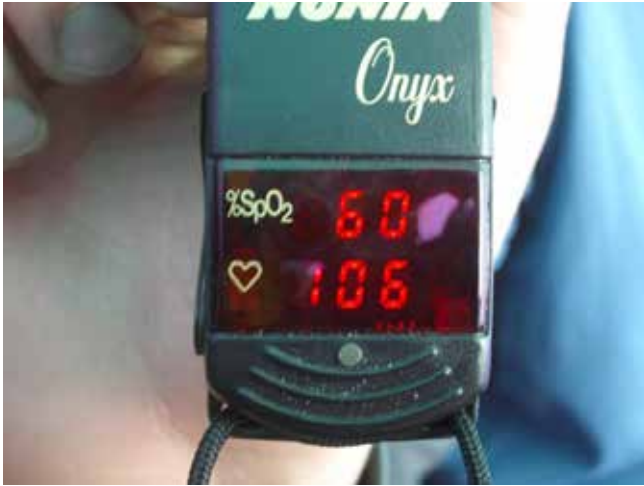General rights
Copyright for the publications made accessible via the Queen's University Belfast Research Portal is retained by the author(s) and / or other copyright owners and it is a condition of accessing these publications that users recognise and abide by the legal requirements associated with these rights.

Take down policy
The Research Portal is Queen's institutional repository that provides access to Queen's research output. Every effort has been made to ensure that content in the Research Portal does not infringe any person's rights, or applicable UK laws. If you discover content in the Research Portal that you believe breaches copyright or violates any law, please contact openaccess@qub.ac.uk.

Curiositas

CRITICAL CARE

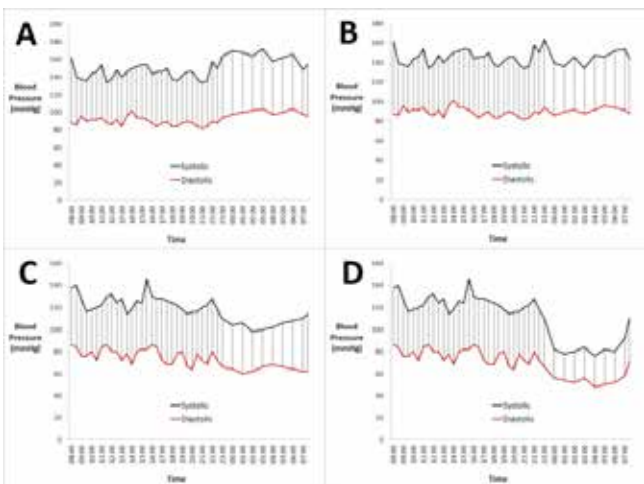
Look at the values of %SpO₂ on the Pulse Oximeter below. Surprisingly the individual was functioning normally at the time of the photo.



The device is working properly and the individual did not have cool peripheries. Can you work out why the reading is so low?

MEDICAL STUDENT QUIZ

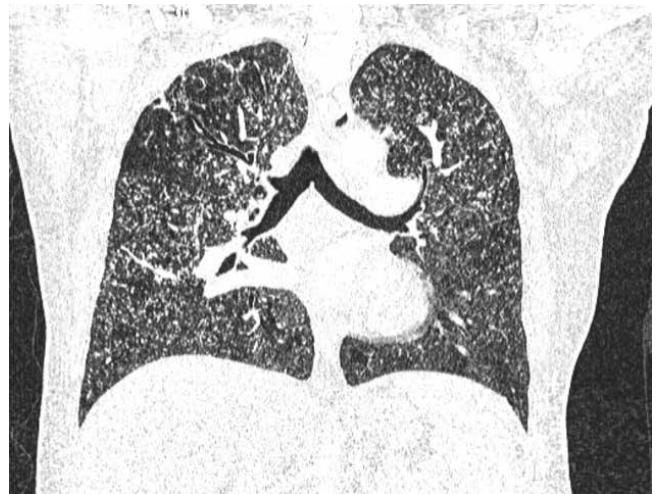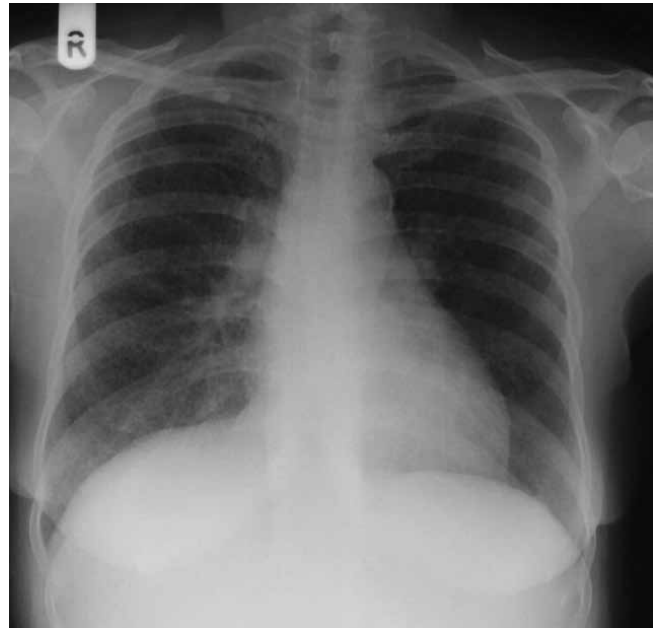A 52 year old man is noted to have high blood pressure and undergoes ambulatory blood pressure monitoring. Four possible sets of results are shown graphically below.



1. Which of these patterns would be classified as normal?
2. What do the other 3 patterns shown demonstrate and what is the significance of such findings?

POSTGRADUATE QUIZ

A 20 year old man presented with increasing lethargy and shortness of breath over the past 6 months after visiting parts of Africa. Recently he has lost weight, developed a fever and headache. His chest x-ray and CT scan of chest are as follows:



1. What is the diagnosis and why is this specific term used?
2. List three differentials, for such an appearance on chest CT/ chest x-ray
3. How is this condition treated?
4. Beyond the respiratory system, which other systems are most commonly involved with this condition?

ANSWERS See overleaf

CONSIDER CONTRIBUTING TO CURIOSITAS?

Please refer to 'Curiositas: Guidelines for contributors' <http://www.ums.ac.uk/curiositas.html> and email umj@qub.ac.uk with your ideas and submissions.

CRITICAL CARE

Under normal circumstances clinical observations such as these would lead the diligent physician to conduct a full clinical assessment and seek to rapidly reverse the cause. At the time of this picture the individual concerned was comfortable, at rest and far from being in extremis. On the morning of May 23, 2007, after having spent 60 days at an elevation higher than 2500m, and having just



summitted Mount Everest (8848m), four climbers on the Caudwell Xtreme Everest Expedition¹ had arterial blood sampling on their descent.

The mean values for the climbers of PaO₂ and PaCO₂ were respectively

24.6mmHg/3.28kPa (Normal ref. 75-100mmHg/10-13.3kPa) and 13.3mmHg/1.77kPa (Normal ref. 35-45mmHg/4.67-6.0kPa); the lowest ever documented in humans. These measurements provide a picture of the pattern of and limits to changes in human blood gases in response to hypobaric hypoxia on the earth's highest mountain. In conjunction with initiating factors and the presence of coexisting conditions, hypoxia triggers numerous adaptive and maladaptive systemic responses that remain poorly understood. The authors suggested that an understanding of the limits of adaptation to hypoxia would be relevant to physicians who care for critically ill patients since many of the interventions aimed at restoring or maintaining cellular oxygenation often prove ineffective and may at times be detrimental.²

1. Grocott M, Richardson A, Montgomery H, Mythen M. Caudwell Xtreme Everest: a field study of human adaptation to hypoxia. *Crit Care* 2007;11:151

2. Grocott M, Martin D, Levett D et al. Arterial Blood Gases and Oxygen Content in Climbers on Mount Everest. *N Engl J Med* 2009; 360:140-149

Dr Nigel Hart (Senior Lecturer, Queen's University Belfast). Dr Hart kindly gave consent for these images to be published.

MEDICAL STUDENT QUIZ

1. Panel C. Blood pressure is within 'normal' limits, and the pressure overnight is around 15% lower than that during the day (normal nocturnal dipping).
2. In Panel B, there is no clear diurnal variation in blood pressure meaning that there is absent nocturnal dipping. Non-dipping can have innocent or pathologic explanations. Perhaps the patient works night shifts, and is asleep during the day, or perhaps the inflation/deflation of the sphygmomanometer cuff caused discomfort and resulted in a very poor night's sleep. Non-dipping has been also associated with obstructive sleep apnoea, diabetes mellitus, obesity, renal failure and other secondary causes of hypertension. In Panel A, the blood pressure is higher overnight than during the day - the so-called 'reverse dipping' pattern, which is again abnormal and in need of investigation. Panel D shows excessive dipping which has been linked with worsening of cardiovascular risk, perhaps due to under-perfusion of vital organs.

Dr Paul Hamilton (Specialty Registrar, Chemical Pathology, Belfast Health and Social Care Trust) and Michael Corr (Medical Student, Queen's University Belfast)

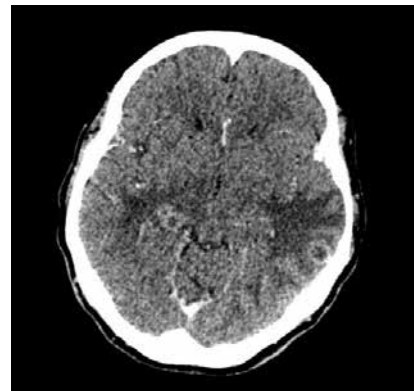
POSTGRADUATE QUESTION

1. Miliary Tuberculosis. The chest x-ray appearances of multiple pulmonary nodules (1-3 mm) is so called due to its similar appearance to 'millet seed'.
2. Infection (e.g. TB, fungal), metastases (e.g. thyroid, renal, breast, melanoma, pancreatic), and sarcoidosis.
3. NICE suggests 2 months of treatment with Isoniazid, Rifampicin, Pyrazinamide and Ethambutol, followed by 4 months with Isoniazid and Rifampicin.
4. Extra-pulmonary sites of infection commonly observed in TB include: lymph nodes, pleura, osteoarticular, skin and liver, although any organs can be involved. There are various central nervous system manifestations, one of which is tuberculomas which could explain this patient's headache.

Tuberculosis (TB), caused by *Mycobacterium tuberculosis*, remains a significant global disease, with protean manifestations, albeit a disease most commonly associated with the respiratory system. One of the more uncommon forms of pulmonary TB is miliary TB, in which tiny deposits form innumerable nodules between 1-3 mms in the lungs. These are typically uniform in size and diffusely distributed in both lungs. This form of the disease often presents in the sickest patients and represents haematogeneous dissemination for which the prognosis is poor. The name miliary arises from the similarity of the appearances in the lungs to that of millet seed. Millet seed is grown for use in feed for the animal industry as well as a health food for humans.



Millet Seed



Axial CT Head with contrast showing tuberculomas

TB is a truly multi-system disease and can manifest in any organ system, including various central nervous system manifestations, one of which is tuberculomas. Cold abscesses of the neck and chest wall are also a recognised presentation.

Dr Ian Bickle (Consultant Radiologist, Raja Isteri Penigran Anak Saleha Hospital, Bandar seri Begawan, Brunei Darussalam) and Glenn Ritchie (Medical Student, Queen's University Belfast)