



**QUEEN'S  
UNIVERSITY  
BELFAST**

## **Retinal arteriolar calibre and venular fractal dimension predict progression of proliferative diabetic retinopathy 6 months after panretinal photocoagulation: a prospective, clinical interventional study**

Torp, T. L., Kawasaki, R., Wong, T. Y., Peto, T., & Grauslund, J. (2021). Retinal arteriolar calibre and venular fractal dimension predict progression of proliferative diabetic retinopathy 6 months after panretinal photocoagulation: a prospective, clinical interventional study. *BMJ open ophthalmology*, [e000661]. <https://doi.org/10.1136/bmjophth-2020-000661>

**Published in:**  
BMJ open ophthalmology

**Document Version:**  
Publisher's PDF, also known as Version of record

**Queen's University Belfast - Research Portal:**  
[Link to publication record in Queen's University Belfast Research Portal](#)

**Publisher rights**  
Copyright 2021 the authors.  
This is an open access Creative Commons Attribution-NonCommercial License (<https://creativecommons.org/licenses/by-nc/4.0/>), which permits use, distribution and reproduction for non-commercial purposes, provided the author and source are cited.

**General rights**  
Copyright for the publications made accessible via the Queen's University Belfast Research Portal is retained by the author(s) and / or other copyright owners and it is a condition of accessing these publications that users recognise and abide by the legal requirements associated with these rights.

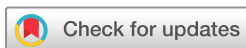**Take down policy**  
The Research Portal is Queen's institutional repository that provides access to Queen's research output. Every effort has been made to ensure that content in the Research Portal does not infringe any person's rights, or applicable UK laws. If you discover content in the Research Portal that you believe breaches copyright or violates any law, please contact [openaccess@qub.ac.uk](mailto:openaccess@qub.ac.uk).

# Retinal arteriolar calibre and venular fractal dimension predict progression of proliferative diabetic retinopathy 6 months after panretinal photocoagulation: a prospective, clinical interventional study

Thomas Lee Torp <sup>1,2</sup>, Ryo Kawasaki <sup>2,3</sup>, Tien Yin Wong <sup>4</sup>, Tunde Peto <sup>2,5</sup>, Jakob Grauslund <sup>1,2,6</sup>

**To cite:** Torp TL, Kawasaki R, Wong TY, *et al.* Retinal arteriolar calibre and venular fractal dimension predict progression of proliferative diabetic retinopathy 6 months after panretinal photocoagulation: a prospective, clinical interventional study. *BMJ Open Ophthalmology* 2021;**6**:e000661. doi:10.1136/bmjophth-2020-000661

Received 15 November 2020  
Revised 2 March 2021  
Accepted 3 March 2021



© Author(s) (or their employer(s)) 2021. Re-use permitted under CC BY-NC. No commercial re-use. See rights and permissions. Published by BMJ.

For numbered affiliations see end of article.

## Correspondence to

Thomas Lee Torp; thomas.lee.torp@rsyd.dk

## ABSTRACT

**Objective** We examined the hypothesis that baseline retinal vascular geometry in patients with proliferative diabetic retinopathy (PDR) predicts disease activity 6 months after panretinal photocoagulation (PRP).

**Methods and analysis** We included 47 eyes from 40 patients with treatment-naïve PDR in a 6-month prospective study. Diagnosis of PDR and disease activity was evaluated by wide-field fluorescein angiography (Optomap, Optos, Dunfermline, Scotland, UK). At baseline and 6-month follow-up, the retinal vessel geometry was measured on optic disc centred images using semiautomated software Vessel Assessment and Measurement Platform for Images of the Retina (VAMPIRE, Dundee, Scotland).

**Results** At baseline, mean age and duration of diabetes was 51.6 and 21.4 years, and 62.5% were men. Seventeen eyes (36.2%) had progression of PDR during follow-up. At baseline, we found higher retinal arteriolar calibre (31.3±0.8 vs 28.8±0.8 pixels, p=0.02) and venous fractal dimension ( $F_D$ ) (1.257±0.011 vs 1.222±0.011, p=0.02) in eyes with progression of PDR as compared with eyes with non-progression. In a multiple logistic regression model, both higher retinal arteriolar calibre (OR 1.34, 95% CI, 1.09 to 1.64, p<0.01) and venular  $F_D$  (OR 1.15, 95% CI, 1.04 to 1.27, p<0.01) predicted progression of PDR. Venular calibre was seen to increase from baseline to month six regardless of disease progression (non-progression 45.0±0.7 vs 52.7±1.8 pixels, p<0.01; progression 46.2±0.8 vs 51.0±1.7 pixels, p<0.01).

**Conclusion** Our prospective study showed that arteriolar calibre and venular  $F_D$  at baseline were predictive of disease activity 6 months after PRP treatment in patients with treatment-naïve PDR.

## INTRODUCTION

Diabetic retinopathy (DR) is a common microvascular complication of diabetes mellitus (DM). DR is a major cause of visual impairment related primarily to either

## Key messages

### What is already known about this subject?

- ▶ Retinal vascular geometry (calibre, tortuosity, fractal dimension) has already been identified as markers for diabetic retinopathy but predicting the outcome in activity of proliferative diabetic retinopathy (PDR) 6 months after panretinal photocoagulation (PRP) is, in the literature, sparse and inconclusive.

### What are the new findings?

- ▶ In this 6-month prospective study, we showed the arteriolar calibre and venular fractal dimension at baseline to predict disease activity 6 months after PRP in patients with treatment-naïve PDR.

### How might these results change the focus of research or clinical practice?

- ▶ Structural retinal arteriolar and venular vessel differences could serve as individual markers of adequacy of PRP treatment in patients with PDR.

diabetic macular oedema or to vitreous haemorrhage/tractional retinal detachment from proliferative DR (PDR).<sup>1 2</sup> These complications are seen more frequently in individuals with poorly controlled diabetes, hypertension and/or long DM duration.<sup>3 4</sup> Long-term epidemiological studies have reported up to 75% will have DR 10 years after diagnosis,<sup>5</sup> particularly in persons with type 1 DM.<sup>6 7</sup>

In the 1970s, the Diabetic Retinopathy Study reported that panretinal photocoagulation (PRP) reduced visual loss by more than 50% in patients with severe PDR.<sup>8</sup> PRP is now the standard of care for eyes with PDR.<sup>9</sup> However, currently all patients are given the same amount of PRP laser treatment. Some patients may, therefore, receive insufficient treatment, while excessive treatment may be

given to others. Patients who receive inadequate PRP might have progression of disease with tractional retinal detachment or vitreous haemorrhage, while others who have excessive PRP may develop side effects like visual field loss, night-blindness or diabetic macular oedema.<sup>10–13</sup> The inability to predict progression of PDR despite PRP remains an important gap in the clinical management of PDR. Furthermore, standard PRP treatment has been challenged by the newer anti-vascular endothelial growth factor (VEGF) therapy. The DRCR.net protocol S demonstrated non-inferiority regarding progression of PDR and Early Treatment Diabetic Retinopathy Study (ETDRS) letters gained at 2-year follow-up.<sup>9</sup>

Advances in retinal imaging technology provide new opportunities to assess the retinal vascular geometry using semiautomated computer software. The literature predominantly reports on two different softwares used for accessing the retinal vascular geometry, namely the Vessel Assessment and Measurement Platform for Images of the Retina software (VAMPIRE, Dundee, Scotland) and the Singapore I Vessel Assessment software (SIVA, National University of Singapore, Singapore). Such algorithms allow for a non-invasive quantitative way to assess the retinal vascular tree. A number of studies have found retinal vascular geometry to be closely related to the presence and severity of DR. Studies have reported on increased DR severity to be linked to narrowing of the arteriolar and widening of the venular vessel calibres,<sup>14–17</sup> increased retinal fractals<sup>18</sup> and changes in tortuosity.<sup>19</sup>

The aim of our study was to predict the outcome of PRP treatment in eyes with PDR using non-invasive structural retinal vascular measurements of fundus photographs. We hypothesise that retinal vessel geometry at baseline could be used to identify patients at risk of progression of PDR after PRP treatment.

## MATERIALS AND METHODS

We conducted a prospective clinical interventional study of 47 eyes from 40 patients with treatment-naïve PDR, who were followed for 6 months at Odense University Hospital, Odense, Denmark. The exclusion criteria were age under 18 years, pregnancy, clinical significant macular oedema or treatment-demanding cataract in the study eye.

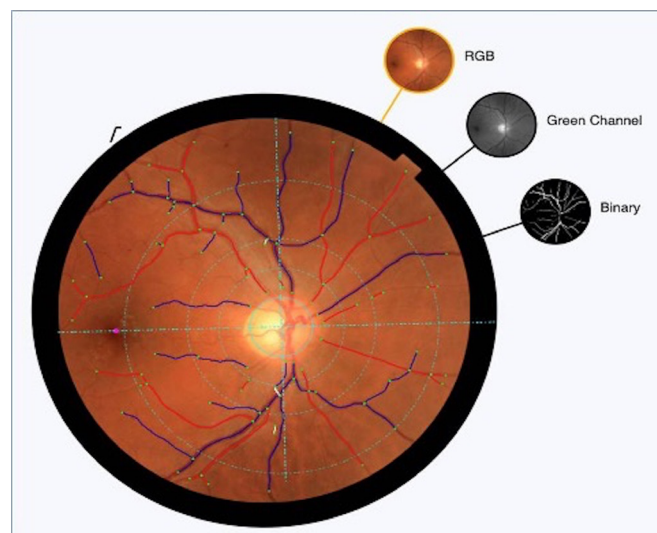
At baseline, all patients provided a full medical history and underwent thorough mydriatic slit lamp examination (tropicamid 10 mg/mL and phenylephrine 10%). Optical coherence tomography (OCT) and fundus photography with 45° optic disc (OD) centred image, were captured by a 3D OCT-2000 Spectral domain OCT (Topcon, Tokyo, Japan), and wide-field fundus images and fluorescein angiography (Optomap; Optos, Dunfermline, Scotland, UK) were performed. The baseline examinations were completed by measurement of blood pressure (Omron 705CP, Hoofdrop, The Netherlands) and haemoglobin A<sub>1c</sub> (HbA<sub>1c</sub>). All examinations were carried out by trained personnel.

After baseline examinations, all patients received PRP in two sessions 1 week apart using a navigated laser-system (NAVILAS, OD-OS GmbH, Berlin, Germany). First laser session was focused in the inferior half of the retina, and the second laser session in the superior half of the retina. Local anaesthetic (oxybuprocain hydrochloride 0.4%) was administered prior to PRP, and a NAVILAS 34 mm or 38 mm contact lens was used during the treatment session. All treatments were given by certified personnel (TLT and JG). All baseline examinations were repeated after 6 months. Progression of PDR was defined as new vessel formation, expanding area of minimum one proliferation or increased area of fluorescein leakage on angiography, as defined by clinical guidelines.

Rescue PRP was given for eyes with progression of PDR at follow-up month three, and progression of PDR was defined as progression at any point during follow-up.

## Image assessment

Fundus images were captured as 45° OD centred images (3D OCT-2000 Spectral domain OCT) acquired at baseline, and month six were used for retinal vessel geometry analyses using the verified semiautomated VAMPIRE software. All images were graded by a single trained grader (TLT) in accordance with the VAMPIRE grading protocol. Details and validation have been reported elsewhere.<sup>20–23</sup> In brief, the software automatically detects the OD and foveal area. If necessary, manual adjustment of the OD and foveal tracing are possible. The software places a three-zoned grid around the OD, located 0.0–2.0 disc diameters from the margin of the OD (figure 1). The



**Figure 1** Vascular Assessment and Measurement Platform for Images of the Retina (VAMPIRE) grid placed on an optic disc centred 45° fundus image. Arterioles and venules are marked by red and blue covers, deleted vessel segments are white. Green dot=vessel-start, vessel-stop or vessel-crossing. Vessel grading is performed between 0.0 and 2.0 disc diameters from the optics disc. Three different image modalities are seen to the right of the fundus image. RGB, red green blue image.

three zones are labelled A–C (zone A 0.0–0.5 disc diameter from the OD, zone B 0.5–1.0 disc diameter from the OD and zone C 1.0–2.0 disc diameter from the OD), and the vessels are automatically traced by the software and labelled as arterioles (red) or venules (blue). Corrections of vessel-labelling and artefacts are done by the grader. We measured the following: central retinal artery and vein calibre (CRAE, CRVE) in zone B using a revised ‘Big-6-formula’,<sup>24</sup> and the vessel tortuosity and fractal dimension ( $F_D$ ) in zone C.

Twenty images were masked and graded twice at two different timepoints by the same grader (TLT). The intra-grader intraclass correlation (ICC) was calculated using CRAE and CRVE. The ICC was found to be of strong agreement (ICC 0.97).

### Statistical analyses

All statistical calculations were performed using STATA V.14.2 (StataCorp), and *p* values under 0.05 were considered statistically significant. If both eyes in one patient presented with PDR, we included both eyes in the study. In order to manage potential intra-group correlation between two eyes from the same patient, we used cluster commands. Cluster commands allow for observations to be independent across groups (clusters) but not necessarily within groups. At baseline, categorical data are presented as percentage and continuous data concerning demographic data as mean with SD. Vessel geometric variables are presented as mean with SD. Differences between patients with progression and non-progression of PDR at baseline and month six were compared by linear regression. Multiple logistic regression was performed with retinal vessel geometry (calibre, tortuosity,  $F_D$ ) as predictors for progression of PDR (with adjustments for sex, age, duration of diabetes, HbA1c and total amount of laser spots). The ICC was calculated using the two-way mixed-effects model.

### RESULTS

We examined 47 eyes from 40 patients. At baseline, mean±SD age and duration of diabetes were 51.6±13.9 and 21.4±11.6 years, and 62.5% were men. Mean±SD HbA1c and blood pressure were 70.9±18.1 mmol/mol and 154/85±22/14 mm Hg. At baseline, we found no difference between eye of the two subsequently formed groups (progression vs non-progression of PDR) in sex, age, duration of diabetes, HbA1c, blood pressure, smoking or total amount of laser spots delivered (table 1).

At baseline, we found a statistically significant higher arteriolar calibre and venous  $F_D$  in eyes with progression of PDR as compared with eyes with non-progression of PDR (calibre: 31.3±0.8 vs 28.8±0.8 pixels, *p*=0.02;  $F_D$ : 1.257±0.011 vs 1.222±0.011, *p*=0.02). In a multiple logistic regression model, a higher baseline retinal arteriolar calibre (OR 1.34 per one point increment, 95% CI 1.09 to 1.64, *p*<0.01) and venular  $F_D$  (OR 1.15 per 0.01 point increment, 95% CI 1.04 to 1.27, *p*<0.01) was independently associated with progression of PDR at follow-up month six.

We found a statistically significant increment in arteriolar and venular calibre in patients with non-progression of PDR from baseline to follow-up month six (arteriolar 28.8±0.8 vs 33.8±1.0 pixels, *p*<0.01; venular 45.0±0.7 vs 52.7±1.8 pixels, *p*<0.01), although this was not seen when performing multiple logistic regression. Furthermore, an increment in retinal venular calibre and arteriolar tortuosity were seen from baseline to follow-up month six in patients with progression of PDR, likewise this was not seen when performing multiple logistic regression (table 2).

### DISCUSSION

In this prospective study of patients with treatment-naive PDR, we found the baseline arteriolar calibre and venous  $F_D$  to be predictive of disease activity 6 months after PRP

**Table 1** Demographic characteristics at baseline as compared with progression of proliferative diabetic retinopathy during the 6-month follow-up

Demographics (40 patients/47 eyes)	Non-progression		Progression		P value
	Mean	SD	Mean	SD	
Patients/eyes, n	27/30		13/17		
Male/female, n	19/8		6/7		0.13
Age, years	53.3	13.9	48.0	14.0	0.25
Duration of diabetes, years	21.8	11.7	20.5	11.6	0.63
HbA1c, mmol/mol	71.9	18.8	68.7	17.3	0.90
Systolic blood pressure, mm Hg	157	24	147	18	0.31
Diastolic blood pressure, mm Hg	86	14	83	14	0.72
Smoker/non-smoker, n	8/19		4/9		0.94
Laser spots, n	1551.0	220.5	1552.0	234.3	0.89
Diabetes type 1/type 2, n	13/14		7/6		0.73

All values are represented as mean±SD. HbA1c, Glycated hemoglobin  
HbA1c, haemoglobin  $A_{1c}$ .





**Table 2** Changes in retinal vascular geometrical variables in patients with non-progression and progression of proliferative diabetic retinopathy 6 months after panretinal photocoagulation

Retinal vessel geometry (47 eyes)		BL			6M		P value
		n	Mean	SD	Mean	SD	
<b>Calibre (pixel)</b>							
Arterial	Non-progression	31	28.8	0.8	33.8	1.0	<0.01*
	Progression	18	31.3	0.8	34.0	0.8	0.03*
	P value		0.02*		0.88		
Venous	Non-progression	31	45.0	0.7	52.7	1.8	<0.01*
	Progression	18	46.2	0.8	51.0	1.7	<0.01*
	P value		0.26		0.54		
<b>Tortuosity</b>							
Arterial	Non-progression	31	-8.14	0.28	-8.18	0.30	0.37
	Progression	18	-7.69	0.49	-8.35	0.11	0.03*
	P value		0.42		0.59		
Venous	Non-progression	31	-7.85	0.40	-8.39	0.07	0.81
	Progression	18	-8.32	0.06	-8.34	0.09	0.68
	P value		0.24		0.59		
<b>Fractal dimension</b>							
Arterial	Non-progression	31	1.210	0.013	1.201	0.014	0.51
	Progression	18	1.225	0.013	1.239	0.014	0.16
	P value		0.38		0.05		
Venous	Non-progression	31	1.222	0.011	1.240	0.008	0.07
	Progression	18	1.257	0.011	1.252	0.014	0.55
	P value		0.02*		0.43		

All values are represented as mean±SD. Differences between patients with non-progression and progression of proliferative diabetic retinopathy are given vertically, and changes from baseline (BL) to follow-up 6 months (6M) (paired data) are represented horizontally.

\*Statistically significant.

treatment. Every 1.0 pixel point in wider arteriolar calibre at baseline was associated with a 34% increased risk of progression of PDR, and every 0.01 point higher  $F_D$  was associated with a 15% increased risk of PDR progression, independent of other risk factors.

In patients with progression of PDR, we found the baseline arteriolar calibre to be wider compared with patients without progression of PDR at follow-up month six. Studies have postulated wider arteriolar calibre as a risk factor in the early development of DR.<sup>15 25</sup> Furthermore, a gradual constriction of the arteriolar calibre has been observed with increased severity of DR.<sup>17 26</sup> In a study by Broe *et al*, it was shown that reduced arteriolar calibres were associated with a 31% cumulative incidence of PDR after 16 years.<sup>27</sup> However, the overall association between arteriolar calibre and DR is more complex, and studies conducted on large cohorts have reported on no associations, or even arteriolar calibre dilatation.<sup>14 28–30</sup> The literature is seen to be very inconclusive regarding retinal arteriolar calibre, in different stages of DR. To our knowledge, no other studies have looked at differences in retinal vascular parameters between patients with and without progression after PDR-treatment. At the level of

PDR, the retinal arteriolar calibre should be expected to be affected by different systemic and microvascular factors. Traditionally systemic risk factors like duration of diabetes, glycaemic and blood pressure control are believed to have an impact on retinal vessel calibre.<sup>31</sup> Our study might indicate that the microvascular capacity is radically changed, when an eye reaches the level of PDR. The hypoxic load increases and neovascularisations are formed. Thus, dilating the arterioles in order to increase the blood flow to the new vessels in eyes with reduced or damaged vascular capacity.

The  $F_D$  explains the complexity of the retinal vascular tree; thus, a higher value equals a higher retinal vascular complexity. At baseline we found a higher  $F_D$  in patients with progression of PDR as compared with patients with non-progression at follow-up month six. This could be due to a higher hypoxic load in patients with progression of PDR 6 months after PRP, thus resulting in a more complex vascular structure. The arteriolar and venular  $F_D$  did not differ between the two groups from baseline to follow-up month six. Earlier studies have reported on a lower  $F_D$  to be associated with a higher risk of developing PDR.<sup>18 27</sup> In an earlier prospective study,

performed at our unit, we found no difference in  $F_D$  at baseline between patients with progression and non-progression at follow-up month six.<sup>32</sup> This difference could be due to the usage of two different computer softwares, the SIVA and VAMPIRE softwares. There are some evident differences between the two softwares. First of all, there is a difference in the postprocessing of retinal images. Furthermore, different mathematical algorithms are used to access the retinal vessel geometry.

Second, the SIVA software allows fare more grader-correction than the VAMPIRE software. The SIVA software allows for tracing of untraced vessels, correction of vessel crossings and deletion of vessel segments. The VAMPIRE software does not allow the abovementioned corrections. McGrory *et al.*<sup>33</sup> reported on the agreement in measurements between the two softwares and concluded that caution should be taken when making inferences regarding the associations between retinal measures.

Furthermore, the arteriolar tortuosity was seen to increase from baseline to follow-up month six in patients with progression of PDR. Likewise, on this matter the literature is inconclusive. One prospective study reported on increased arteriolar tortuosity in patients with progression of PDR 6 months after PRP treatment, while another cross-sectional study found no association between PDR and retinal vascular tortuosity.<sup>32</sup> One could speculate, if increased tortuosity could be associated with increased retinal ischaemia. Thereby the tortuosity would increase in patients with an increased or high ischaemic load and progression of PDR in this group is seen despite PRP treatment.

In our study, the arteriolar calibre was documented to increase from baseline to follow-up month six in the two groups regardless of PRP treatment. As stated earlier, it has been reported that the arteriolar vessel calibre decreases with increased severity of DR.<sup>17 26</sup> Thus, narrow arteriolar vessels could be expected at the level of PDR. After PRP treatment, the ischaemic drive is thought to be reduced, and thereby a dilatation of the retinal vessels could be seen. In our study, the dilatation of the retinal vessels regardless of progression of PDR at follow-up month six could be due to the laser treatment itself. In a study by Klein *et al.*,<sup>26</sup> the arteriolar calibre was found to be significantly smaller in eyes with PDR treated with PRP as compared with untreated eyes, although the time from PRP treatment to calibre measurement was unclear.

The venular calibre increased from baseline to month six regardless of disease progression. The literature is somewhat sparse on this topic. Prospective studies have reported on wider retinal venular calibre and increased incidence of PDR.<sup>14 34</sup> However, a prospective study performed at our department on patients with PDR found no statistical change in retinal venular calibre at 6-month follow-up after PRP treatment regardless of disease progression.<sup>32</sup> A change in the retinal venular calibre was not expected. Our findings showed an increase in the venular calibre that could be explained by a reduced

autoregulatory function due to the long duration of DM, and the overall state of the vessels at the point of PDR.

The strengths of this study were the prospective design, and the use of a semiautomated validated computer software which minimised grader influence on the results. Limitations include the lack of refractive data on the cohort, and the relatively small sample size; larger cohorts are needed to investigate the disease process and its vascular characteristics further.

In conclusion, our prospective study showed that the arteriolar calibre and venular  $F_D$  at baseline, using the VAMPIRE software, predict disease activity 6 months after PRP treatment in patients with treatment-naïve PDR. We found increased retinal arteriolar and venular calibre from baseline to follow-up month six regardless of PRP treatment. Hence, structural retinal arteriolar and venular differences/changes could serve as individual markers of adequacy of PRP treatment in patients with PDR.

#### Author affiliations

<sup>1</sup>Department of Ophthalmology, Odense Universitetshospital, Odense, Denmark

<sup>2</sup>Department of Clinical Research, University of Southern Denmark, Odense, Denmark

<sup>3</sup>Department of Vision Informatics, Osaka University School of Medicine Graduate School of Medicine, Suita, Osaka, Japan

<sup>4</sup>Singapore Eye Research Institute, Singapore National Eye Center, Duke-NUS Medical School, National University of Singapore, Singapore

<sup>5</sup>Centre for Public Health, Blackwell's Queen's University Belfast, Belfast, UK

<sup>6</sup>Steno Diabetes Center, Odense University Hospital, Odense, Denmark

**Acknowledgements** This work was supported by The Velux Foundation and The Region of Southern Denmark. None of the funders have been involved in any decisions regarding this study, and the authors declare no duality of interest associated with this article.

**Contributors** All authors contributed to the formation of the study, and the execution of the manuscript. TLT and JG performed all patient examinations, laser treatment and collection of data.

**Competing interests** None declared.

**Patient consent for publication** Not required.

**Ethics approval** The study was conducted in accordance with the criteria of the Helsinki II Declaration and good clinical practice. Due to the interventional design of the study, it was not appropriate or possible to involve patients or the public in the design. Patients were only involved in the study as participants in the cohort, and were not involved in the design, conduct or reporting of the study, as this was done by the study group. It was approved by the Regional (Southern) Scientific Ethics Committee (ID S-20140046), The Danish Data Protection Agency (ID 14/16546) and registered at Clinical Trials (ID NCT02157350).

**Provenance and peer review** Not commissioned; externally peer reviewed.

**Data availability statement** Data are available upon request.

**Open access** This is an open access article distributed in accordance with the Creative Commons Attribution Non Commercial (CC BY-NC 4.0) license, which permits others to distribute, remix, adapt, build upon this work non-commercially, and license their derivative works on different terms, provided the original work is properly cited, appropriate credit is given, any changes made indicated, and the use is non-commercial. See: <http://creativecommons.org/licenses/by-nc/4.0/>.

#### ORCID iDs

Thomas Lee Torp <http://orcid.org/0000-0002-3556-8531>

Ryo Kawasaki <http://orcid.org/0000-0002-7492-6303>

Tien Yin Wong <http://orcid.org/0000-0002-8448-1264>

Tunde Peto <http://orcid.org/0000-0001-6265-0381>

Jakob Grauslund <http://orcid.org/0000-0001-5019-0736>

## REFERENCES

- 1 Bressler SB, Beaulieu WT, Glassman AR, *et al*. Photocoagulation versus ranibizumab for proliferative diabetic retinopathy: should baseline characteristics affect choice of treatment? *Retina* 2019;39:1646-1654.
- 2 Grauslund J, Green A, Sjølie AK. Prevalence and 25 year incidence of proliferative retinopathy among Danish type 1 diabetic patients. *Diabetologia* 2009;52:1829-35.
- 3 Klein R, Lee KE, Knudtson MD, *et al*. Changes in visual impairment prevalence by period of diagnosis of diabetes: the Wisconsin epidemiologic study of diabetic retinopathy. *Ophthalmology* 2009;116:1937-42.
- 4 Antonetti DA, Klein R, Gardner TW. Diabetic retinopathy. *N Engl J Med* 2012;366:1227-39.
- 5 Klein R, Klein BE, Moss SE, *et al*. The Wisconsin epidemiologic study of diabetic retinopathy. XV. The long-term incidence of macular edema. *Ophthalmology* 1995;102:7-16.
- 6 Klein R, Klein BE, Moss SE, *et al*. The Wisconsin epidemiologic study of diabetic retinopathy. II. prevalence and risk of diabetic retinopathy when age at diagnosis is less than 30 years. *Arch Ophthalmol* 1984;102:520-6.
- 7 Klein R, Klein BE, Moss SE, *et al*. The Wisconsin epidemiologic study of diabetic retinopathy. III. prevalence and risk of diabetic retinopathy when age at diagnosis is 30 or more years. *Arch Ophthalmol* 1984;102:527-32.
- 8 Preliminary report on effects of photocoagulation therapy. The diabetic retinopathy study Research Group. *Am J Ophthalmol* 1976;81:383-96.
- 9 Gross JG, Glassman AR, *et al*, Writing Committee for the Diabetic Retinopathy Clinical Research Network. Panretinal photocoagulation vs Intravitreal ranibizumab for proliferative diabetic retinopathy: a randomized clinical trial. *JAMA* 2015;314:2137-46.
- 10 Photocoagulation treatment of proliferative diabetic retinopathy. clinical application of diabetic retinopathy study (DRS) findings, DRS report number 8. the diabetic retinopathy study Research Group. *Ophthalmology* 1981;88:583-600.
- 11 Ferris FL, Podgor MJ, Davis MD. Macular edema in diabetic retinopathy study patients. diabetic retinopathy study report number 12. *Ophthalmology* 1987;94:754-60.
- 12 Early photocoagulation for diabetic retinopathy. ETDRS report number 9. early treatment diabetic retinopathy study Research Group. *Ophthalmology* 1991;98:766-85.
- 13 Pahor D. Visual field loss after argon laser panretinal photocoagulation in diabetic retinopathy: full- versus mild-scatter coagulation. *Int Ophthalmol* 1998;22:313-9.
- 14 Klein R, Klein BEK, Moss SE, *et al*. The relation of retinal vessel caliber to the incidence and progression of diabetic retinopathy: XIX: the Wisconsin epidemiologic study of diabetic retinopathy. *Arch Ophthalmol* 2004;122:76-83.
- 15 Rogers SL, Tikellis G, Cheung N, *et al*. Retinal arteriolar caliber predicts incident retinopathy: the Australian diabetes, obesity and lifestyle (AusDiab) study. *Diabetes Care* 2008;31:761-3.
- 16 Klein R, Klein BEK, Moss SE, *et al*. Retinal vessel caliber and microvascular and macrovascular disease in type 2 diabetes: XXI: the Wisconsin epidemiologic study of diabetic retinopathy. *Ophthalmology* 2007;114:1884-92.
- 17 Grauslund J, Hodgson L, Kawasaki R, *et al*. Retinal vessel calibre and micro- and macrovascular complications in type 1 diabetes. *Diabetologia* 2009;52:2213-7.
- 18 Grauslund J, Green A, Kawasaki R, *et al*. Retinal vascular fractals and microvascular and macrovascular complications in type 1 diabetes. *Ophthalmology* 2010;117:1400-5.
- 19 Sasongko MB, Wong TY, Nguyen TT, *et al*. Retinal vascular tortuosity in persons with diabetes and diabetic retinopathy. *Diabetologia* 2011;54:2409-16.
- 20 Perez-Rovira A, MacGillivray T, Trucco E, *et al*. Vampire: vessel assessment and measurement platform for images of the retina. *Annu Int Conf IEEE Eng Med Biol Soc* 2011;2011:3391-4.
- 21 Patton N, Aslam TM, MacGillivray T, *et al*. Retinal image analysis: concepts, applications and potential. *Prog Retin Eye Res* 2006;25:99-127.
- 22 Lisowska A, Annunziata R, Loh GK, *et al*. An experimental assessment of five indices of retinal vessel tortuosity with the RET-TORT public dataset. *Annu Int Conf IEEE Eng Med Biol Soc* 2014;2014:5414-7.
- 23 MacGillivray TJ, Patton N, Doubal FN, *et al*. Fractal analysis of the retinal vascular network in fundus images. *Annu Int Conf IEEE Eng Med Biol Soc* 2007;2007:6456-9.
- 24 Knudtson MD, Lee KE, Hubbard LD, *et al*. Revised formulas for summarizing retinal vessel diameters. *Curr Eye Res* 2003;27:143-9.
- 25 Cheung N, Rogers SL, Donaghue KC, *et al*. Retinal arteriolar dilation predicts retinopathy in adolescents with type 1 diabetes. *Diabetes Care* 2008;31:1842-6.
- 26 Klein R, Klein BEK, Moss SE, *et al*. Retinal vascular caliber in persons with type 2 diabetes: the Wisconsin epidemiological study of diabetic retinopathy: XX. *Ophthalmology* 2006;113:1488-98.
- 27 Broe R, Rasmussen ML, Frydkjaer-Olsen U, *et al*. Retinal vascular fractals predict long-term microvascular complications in type 1 diabetes mellitus: the Danish cohort of pediatric diabetes 1987 (DCPD1987). *Diabetologia* 2014;57:2215-21.
- 28 Crosby-Nwaobi R, Heng LZ, Sivaprasad S. Retinal vascular calibre, geometry and progression of diabetic retinopathy in type 2 diabetes mellitus. *Ophthalmologica* 2012;228:84-92.
- 29 Islam FMA, Nguyen TT, Wang JJ, *et al*. Quantitative retinal vascular calibre changes in diabetes and retinopathy: the Singapore Malay eye study. *Eye* 2009;23:1719-24.
- 30 Yang X, Deng Y, Gu H, *et al*. Relationship of retinal vascular calibre and diabetic retinopathy in Chinese patients with type 2 diabetes mellitus: the Desheng diabetic eye study. *Br J Ophthalmol* 2016;100:1359-65.
- 31 Cheung N, Mitchell P, Wong TY. Diabetic retinopathy. *Lancet* 2010;376:124-36.
- 32 Torp TL, Kawasaki R, Wong TY, *et al*. Temporal changes in retinal vascular parameters associated with successful panretinal photocoagulation in proliferative diabetic retinopathy: a prospective clinical interventional study. *Acta Ophthalmol* 2018;96:405-10.
- 33 McGroarty S, Taylor AM, Pellegrini E, *et al*. Towards standardization of quantitative retinal vascular parameters: comparison of SIVA and vampire measurements in the Lothian birth cohort 1936. *Transl Vis Sci Technol* 2018;7:12.
- 34 Roy MS, Klein R, Janal MN. Retinal venular diameter as an early indicator of progression to proliferative diabetic retinopathy with and without high-risk characteristics in African Americans with type 1 diabetes mellitus. *Arch Ophthalmol* 2011;129:8-15.